


CHILDREN'S MEMORIAL HERMANN HOSPITAL PEDIATRIC NEUROSCIENCE JOURNAL

A PUBLICATION OF CHILDREN'S MEMORIAL HERMANN HOSPITAL AND MCGOVERN MEDICAL SCHOOL AT UTHEALTH



IN THIS ISSUE

01 True Stories of Strength, Courage
and Perseverance

FEATURES

02 A Few Minutes to Live

04 In Real Life You Don't Quit

RESEARCH

06 Two Novel Studies Seek to Improve
Outcomes in Children with
Malignant Fourth Ventricular
Brain Tumors

07 Designing a Regenerative Patch for
In-utero Spina Bifida Repair

NEWS OF NOTE

10 Dr. David Sandberg Receives Ian's
Friends Foundation Award

Dr. Manish N. Shah Named a Texas
Super Doctors Rising Star

Report on the 2018 Run for the Rose

11 Memorial Hermann and UTHealth
Welcome Dr. Bangning Yu

AANS/CNS Pediatric Neurological
Surgery Section Meeting Held in
Houston

12 Children's Memorial Hermann
Hospital and Mischer
Neuroscience Institute Sponsor
Pediatric Epilepsy Seminar

13 SELECTED PUBLICATIONS

TRUE STORIES *of* STRENGTH, COURAGE *and* PERSEVERANCE

It's a great honor to save a life. Our ability to bring children back from the brink of death after neurological injury depends on the rapid response of people in the community, the vast experience of the Memorial Hermann Life Flight® crew and Greater Houston's EMS teams, and the physicians affiliated with the Level I Pediatric Trauma Center at Children's Memorial Hermann Hospital. In the case of childhood stroke and other critical neurological injuries, the team has logged an outstanding track record of moving young patients from the doors of the Memorial Hermann Red Duke Trauma Institute to CT angiogram to the OR fast – often in 10 minutes or less.

We're grateful to the Wehby family for sharing the story of their 12-year-old son, Luc, who had a stroke when a previously undiagnosed arteriovenous malformation ruptured. Dr. Manish N. Shah saved his life in a challenging operation. After recovering, Luc had Gamma Knife® radiosurgery at Mischer Neuroscience Institute at Memorial Hermann-Texas Medical Center to shrink the AVM. It's no less a privilege to improve quality of life for children with epilepsy. With a complex medical history that includes neurofibromatosis type 1, a stroke caused by moyamoya disease, scoliosis and many years of weekly seizures, Louisiana resident Jordyn Bennett underwent laser ablation surgery performed by Dr. Shah after video EEG testing by Dr. Gretchen Von Allmen. Today the 19-year-old is seizure-free. A special thanks to Jordyn and her mother, Wendi Bennett, for contributing their story to this issue of the *Pediatric Neuroscience Journal*.

UTHealth clinicians and investigators are pioneers in developing new treatments for children with malignant brain tumors. This issue highlights two novel clinical trials under way at our center. One investigates the safety and efficacy of combination methotrexate and etoposide infusions into the fourth ventricle in children with recurrent posterior fossa brain tumors. In the other, we hope to establish the safety and efficacy of direct administration of 5-azacytidine into the fourth ventricle in children with recurrent posterior fossa ependymoma.

We also highlight Dr. Ramesh Papanna and Dr. Stephen Fletcher's novel research to improve the neurological outcomes of children who undergo in-utero spina bifida repair with a patch. At present fewer than half of those who undergo fetal repair show improvement in spinal cord function. Their goal is to take that number to 100 percent.

We hope you find the articles in this issue of our journal interesting and useful. If you have questions about any of our programs, please feel free to contact us directly.

With best wishes,



DAVID I. SANDBERG, MD, FAANS, FACS, FAAP

Professor and Director of Pediatric Neurosurgery
Dr. Mamie Rose Professorship in Pediatric Neurosurgery
Department of Pediatric Surgery and Vivian L. Smith Department of Neurosurgery
McGovern Medical School at UTHealth, Children's Memorial Hermann Hospital and Mischer
Neuroscience Institute at Memorial Hermann-Texas Medical Center

Co-director, Pediatric Brain Tumor Program
The University of Texas MD Anderson Cancer Center
713.500.7370



IAN J. BUTLER, MD

Professor and Director of Child and Adolescent Neurology
Distinguished Chair in West Syndrome Research
McGovern Medical School at UTHealth
713.500.7142

A FEW MINUTES *to* LIVE

An astute school nurse, fast transport to Children's Memorial Hermann Hospital in a specially equipped pediatric air ambulance and nine minutes to the operating table saved the life of 12-year-old Luc Wehby.

Luc came home after school on May 10, 2017, and asked his mother what a migraine feels like. "He had never complained of headaches, and he was not even frequently ill," Jacquie Wehby says. "Now when he looks back, he remembers feeling 'foggy headed' in the past."

That night Luc did his homework and went to his church youth group. The following morning he appeared normal; he ate breakfast and went to school. Shortly after 11 a.m., his mother got a call from the school nurse. Her son had complained of head pain, and as he was

being carried off the Life Flight helicopter into the ER. I didn't really get to see him until seven-and-a-half hours later in the ICU."

Wehby learned later that her son was comatose and on the brink of death when he arrived at the Level 1 Pediatric Trauma Center at Children's Memorial Hermann Hospital. Born with a previously undiagnosed arteriovenous malformation, Luc was one of the more than 50 percent of patients who have an AVM that ruptures, causing an intracranial hemorrhage.

Pediatric neurosurgeon Manish N. Shah, MD, was at the hospital when Luc arrived. "He had a very large hemorrhage deep below the surface on the right side of his brain," says Dr. Shah, who directs the Pediatric Epilepsy Surgery Program and the Texas Comprehensive Spasticity Center at Children's Memorial Hermann

"IN THE OR WE MOVED QUICKLY. WE ESTIMATED THAT WE HAD ONLY A FEW MINUTES TO SAVE HIS LIFE. THANKS TO THE CT ANGIOGRAM, WE WERE ABLE TO REMOVE THE BLOOD CLOT SAFELY TO LOWER HIS INTRACRANIAL PRESSURE."

being walked to the nurse's office, he stopped for a drink of water from a hallway fountain. The nurse saw him go down on one knee, screaming that his head hurt. He went limp on his left side and water dribbled from the left corner of his mouth. Recognizing the signs of stroke, she called 911.

"It all happened very fast," Wehby recalls. "My husband was traveling overseas, and I was on the road when I got the call. I headed for the school. By then Luc was intubated in an ambulance and en route to Kingwood Medical Center, where Memorial Hermann Life Flight® was waiting for him. They told me to turn around and head for the Texas Medical Center, and I got there in time to see Luc

Hospital, the Mischer Neuroscience Institute and McGovern Medical School at UTHealth. "In less than 10 minutes we had the results of his CT angiogram and he was on the operating table being prepped for a decompressive craniectomy - removal of a portion of the skull to reduce damage to healthy areas of the brain by allowing it to swell without being squeezed. In the OR we moved quickly. We estimated that we had only a few minutes to save his life. Thanks to the CT angiogram, we were able to remove the blood clot safely to lower his intracranial pressure. We left the bone flap off, with plans to replace it after the swelling receded."

The morning after the surgery, P. Roc Chen, MD, performed a cerebral



MANISH N. SHAH, MD

Director, Pediatric Spasticity and Epilepsy Surgery
Assistant Professor, Division of Pediatric Neurosurgery
McGovern Medical School at UTHealth



P. ROC CHEN, MD

Associate Professor, Vivian L. Smith Department of Neurosurgery
McGovern Medical School at UTHealth

angiogram, which showed that the AVM was positioned on the optic nerve and frontal lobe, making surgical removal impossible. Dr. Chen is a board-certified neurosurgeon who subspecializes in endovascular, cerebrovascular and skull base neurosurgery, and has expertise in AVMs, brain aneurysms, carotid disease, acoustic neuroma and skull base tumors. Luc's multidisciplinary treatment team agreed that Gamma Knife® radiosurgery was the best option, but first he would need time to recover from the craniectomy.

After nearly two weeks at Children's Memorial Hermann Hospital, Luc was admitted to Shriners Hospital for Children - Houston, which provides specialized care and rehabilitation for children with orthopedic conditions, brain injuries, spinal cord injuries and burns. On June 15, after three weeks at Shriners, he developed intracranial swelling and went back to Children's Memorial Hermann for a CT scan. Because Luc was not reabsorbing cerebrospinal fluid - a common occurrence after brain surgery for a large hemorrhage - Dr. Shah placed a ventriculoperitoneal shunt to relieve pressure on his brain. On June 22, Dr. Shah replaced the surgically removed portion of his skull, and Luc went home four days later.

In mid-July, he was back at Children's Memorial Hermann Hospital and Mischer Neuroscience Institute for the scheduled MRI and Gamma Knife radiosurgery. The surgery was performed by Dr. Chen and radiation oncologist Angel Blanco, MD, a clinical assistant professor in the department of Internal Medicine, division of Oncology at McGovern Medical School.



“With Gamma Knife radiosurgery, we don’t see results in dissipating the AVM area for up to two years, so we will monitor his progress,” says Dr. Shah, who holds a faculty appointment in the department of Pediatric Surgery at UTHealth. “Because Luc was treated so quickly, the permanent deficits he might have suffered were greatly reduced. But the stroke left him with paralysis on his dominant side, and recovery is an ongoing process.”

Luc goes to therapy every day, working to overcome paralysis in his left hand and foot. He wears an ankle-foot orthosis, a brace made of plastic on the lower leg and foot to support his ankle in the correct position. “He takes small steps and is progressing in the use of his arm and hand,” his mother says. “He gets schooling four days a week for an hour each day and tackles his main subjects with enthusiasm. He’s very athletic – a baseball player and Astros fan – and he likes the outdoors, whether it’s riding his motocross bike or hunting and fishing. When we take him fishing, he uses a wheelchair with a rod holder for his right hand – we

hope he’ll come out of this journey ambidextrous. We do everything we can to set him up for success and then watch him hit those milestones. They may seem small, but they’re big to us. We look at this as just a season in his life.”

Dr. Shah credits Luc’s recovery with his positive outlook and hard work in therapy, the rapid response of the school nurse who recognized the signs of stroke and the pediatric emergency team at Children’s Memorial Hermann Hospital, which has logged an outstanding track record of moving patients with critical neurological problems from the doors of the ER to CT angiogram to the OR fast – often in 10 minutes or less.

“Luc gets up every day ready to tackle whatever comes his way,” Jacquie Wehby says. “He said to us that he’s not accepting anything less than 100 percent recovery. His big hope is to go back to baseball. We work very hard with him and are as positive as a family can be. His life changed overnight, and he has a story to tell that will help other children and adults. He’s pretty incredible. Actually, he’s blowing us away.”

Luc Wehby, Astros fan and fisherman, is doing well after a stroke thanks to fast transport to Children’s Memorial Hermann Hospital and the rapid response of physicians at the hospital’s Level I Pediatric Trauma Center.

IN REAL LIFE YOU DON'T QUIT

At 18, Jordyn Bennett was on the borderline between childhood and adulthood when she was referred to pediatric epileptologist Gretchen Von Allmen, MD, and pediatric neurosurgeon Manish N. Shah, MD. The two physicians work together with other adult and pediatric epilepsy specialists at Mischer Neuroscience Institute at Memorial Hermann-Texas Medical Center and Children's Memorial Hermann Hospital, where they manage patients over the entire lifespan for a seamless transition of care. Jordyn is among the many patients to benefit from a highly specialized multidisciplinary program where complex cases are the norm.

Her medical record begins at age one with a diagnosis of neurofibromatosis type 1, a condition characterized by changes in skin pigmentation and the growth of

Jordyn Bennett, whose medical record begins at age one, benefited from the highly specialized multidisciplinary team at Children's Memorial Hermann Hospital.

tumors along nerves in the skin, brain and other parts of the body. NF1 is also associated with scoliosis, short stature and learning disabilities.

A year and a half later, on Mother's Day, Jordyn had a stroke and was diagnosed with moyamoya disease, a rare, progressive cerebrovascular disorder caused by blocked arteries at the base of the brain. In children, its first symptom is often stroke or recurrent transient ischemic attacks. Shortly after the stroke, she began having seizures and was started on antiepileptic drugs; she failed one after another.

In her early life Jordyn saw physicians in New Orleans, a 90-minute drive from her family's home in Walker, Louisiana. "I've always done whatever I had to do to take good care of her," says her mother, Wendi Bennett. "I'm so used to dealing with rare diseases that I hardly know what to do for normal childhood illnesses."

At the age of four, Jordyn underwent surgery for moyamoya disease at Tulane Medical Center, where neurosurgeons split a temporal artery and sutured it to her brain to create blood flow. The

revascularization surgery was successful, and like the majority of children who undergo the procedure, she had no further strokes or problems related to moyamoya.

When she was seven, she developed plexiform neurofibroma, an uncommon variant of neurofibroma associated with multiple nerve bundles. The tumors grew on her spine, causing scoliosis, and she underwent realignment surgery.

Meanwhile, she continued having seizures weekly and sometimes daily. In February 2016, she developed a malignant peripheral nerve sheath tumor in her abdomen and was referred to Houston to John Slopis, MD, medical director of the Neurofibromatosis Program at The University of Texas MD Anderson Cancer Center. The tumor was surrounded by a benign neurofibroma, and no additional treatment was needed.

It was Dr. Slopis who referred the Bennetts to Dr. Gretchen Von Allmen, chief of pediatric epilepsy for the Texas Comprehensive Epilepsy Program and medical director of the Children's Memorial Hermann Hospital Pediatric Epilepsy Monitoring Unit. She scheduled Jordyn for a Phase 1 epilepsy study



using video electroencephalography to assess her condition and determine the best treatment.

“After failing trials of two or more antiepileptic drugs at maximum tolerated doses, a child is considered to have medically intractable epilepsy,” says Dr. Von Allmen, an associate professor in the department of Pediatrics at McGovern Medical School at UTHealth. “Patients are admitted to the Epilepsy Monitoring Unit for three days to a week – rarely more than that – to determine where the seizures are originating and whether surgery is an option. In Jordyn’s case, within three days we were able to capture the seizure she was having multiple times a week. If all the seizures look similar on video EEG, it’s often an indication that one area in the brain is the primary focus.”



GRETCHEN VON ALLMEN, MD

Director, Pediatric Epilepsy Program; Medical Director, Memorial Hermann Pediatric Epilepsy Monitoring Unit; Associate Professor, Division of Pediatric Neurology McGovern Medical School at UTHealth

During their stay in Houston, they also met Dr. Manish N. Shah, who directs the Pediatric Epilepsy Surgery Program and the Texas Comprehensive Spasticity Center at Children’s Memorial Hermann Hospital, the Mischer Neuroscience Institute and McGovern Medical School. “We hypothesized that the seizures could be originating in one of a few regions around her speech network, which is distributed around the brain,” says Dr. Shah, an assistant professor in the department of Pediatric Surgery. “Normally we monitor the language network by implanting subdural grids, but we were concerned that open surgery would be impossible because of her previous surgery for moyamoya. Because of our closely integrated team, we were able to schedule a cerebral angiogram immediately to determine blood flow from the temporal artery. We could see that little blood vessels had formed to supply the brain. A craniotomy would have interfered with that blood supply and put Jordyn at risk for stroke.”



MANISH N. SHAH, MD

*Director, Pediatric Spasticity and Epilepsy Surgery
Assistant Professor, Division of Pediatric Neurosurgery
McGovern Medical School at UTHealth*

Bennett confesses to “googling everything” and had prepared her daughter for the open surgery. “When I found out they couldn’t implant the subdural grids, I was upset,” she says. “I thought, ‘How am I

We close with a single suture, and the patient stays overnight. Laser ablation is a useful tool in our armamentarium, and we have extensive experience with it.”

After the laser ablation surgery, Jordyn’s typical seizures stopped. Six months later she was admitted to the Epilepsy Monitoring Unit at Children’s Memorial Hermann Hospital for a 23-hour video EEG to confirm the procedure’s success. “There was no evidence of

“BEFORE THE AVAILABILITY OF LASER SURGERY, THERE WOULD HAVE BEEN LITTLE WE COULD HAVE DONE FOR JORDYN. INSTEAD, WITH NEUROENDOVASCULAR, NEUROSURGERY AND EPILEPSY SPECIALISTS ALL WORKING TOGETHER, WE WERE ABLE TO GIVE HER THE BEST POSSIBLE RESULT.”

going to tell my child she can’t have that surgery when she was so pumped to have it?” She asked me what would happen now.”

At the multidisciplinary epilepsy surgery conference, her team of physicians and radiologists reviewed the results of her video EEG, MRI and angiogram and decided the only option was laser surgery. “Jordyn’s condition – mesial temporal sclerosis – has the most common association with intractable temporal lobe epilepsy,” Dr. Shah says. “In adults, this particular pathology responds well to laser ablation, but in children it’s not as effective so we usually recommend open temporal lobectomy. But at 18, she was in the gray zone between childhood and adulthood, and no longer truly a child. We believed it would work.”

On May 30, 2017, Dr. Shah took Jordyn to the OR and performed a minimally invasive stereotactic laser ablation of the hippocampus in the temporal lobe. With his patient’s head immobilized in a frame, he inserted a laser fiber the size of a coffee stirrer through a burr hole in her skull.

“The frame allows for extraordinary precision in placing the laser fiber, and using the MR scanner and MR thermometry, we very slowly destroyed the tissue causing the seizures,” he says. “The actual treatment takes 10 to 15 minutes.

any new seizure activity, and she has no deficits or complications from the procedure,” Dr. Von Allmen says. “Before the availability of laser surgery, there would have been little we could have done for her. Instead, with neuroendovascular, neurosurgery and epilepsy specialists all working together, we were able to give her the best possible result. Most patients who remain seizure free for one to two years after surgery can stop their medication.”

A senior in high school, Jordyn plans to graduate this year. “She’s a trooper,” her mother says. “Neurofibromatosis comes with learning disabilities, and she has some. She’s fighting to do her best. When people ask me why I don’t let her drop out of school and go for a GED, I say because in real life you don’t quit. Last year she missed 82 days and still passed, so I tell her, ‘You’ve come this far, and you’ve got to keep fighting.’ And that’s what she does.

“She’s tiny – at 19 she weighs 95 pounds – but if you meet her, you would never guess there’s anything wrong with her,” Bennett says. “I thank God every day for the doctors she’s had in her life. Dr. Shah and Dr. Von Allmen are terrific and know their stuff. I’m ecstatic for my daughter and pray to God that we keep going down the same path. I couldn’t be prouder of her.”

RESEARCH

Two Novel Studies Seek to Improve Outcomes in Children with Malignant Fourth Ventricular Brain Tumors

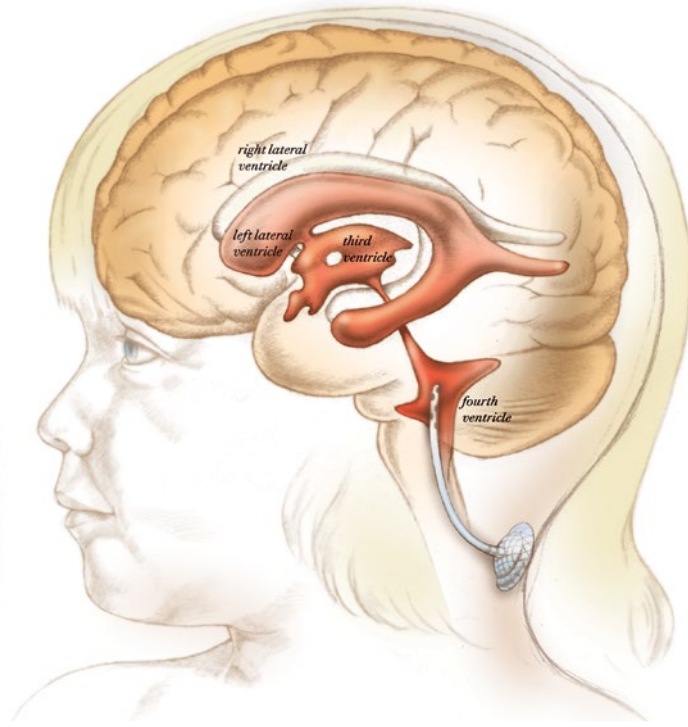
The current outlook for children with recurrent malignant brain tumors originating from the posterior fossa is extremely poor. Most clinical trials offer systemic chemotherapy or re-irradiation, both of which can have a variety of side effects and most often fail in children with recurrent tumors. Two single-center trials under way at Children's Memorial Hermann Hospital and McGovern Medical School at UTHealth are investigating novel therapies with the potential to improve outcomes for children with fourth ventricular brain tumors while avoiding systemic toxicity.



DAVID SANDBERG, MD, FAANS, FACS, FAAP
 Director, Pediatric Neurosurgery; Professor and Chief, Division of Pediatric Neurosurgery; Dr. Marnie Rose Professorship in Pediatric Neurosurgery
 McGovern Medical School at UTHealth

Conducted by David Sandberg, MD, FAANS, FACS, FAAP, professor and director of pediatric neurosurgery at Children's Memorial Hermann Hospital, the Mischer Neuroscience Institute at Memorial Hermann-Texas Medical Center and UTHealth, the first trial, "A Combination Intraventricular Chemotherapy Pilot Study," is investigating methotrexate and etoposide infusions into the fourth ventricle in children with recurrent posterior fossa brain tumors. The trial is open to patients age 1 to 80 with recurrent medulloblastoma, recurrent ependymoma and recurrent atypical teratoid/rhabdoid tumors involving the brain and/or spine.

"Despite advances in pediatric neuro-oncology, we're still seeing too many children die of malignant brain tumors, and the treatments currently available are not satisfactory for children," says Dr. Sandberg, who holds the Dr. Marnie Rose



Professorship in Pediatric Neurosurgery at UTHealth. "Many suffer extreme toxicity from chemotherapy and radiation, and I believe we can do better. Novel approaches are needed to improve treatment outcomes."

The primary objective of the trial is to determine if combination intraventricular infusions of two agents - methotrexate and etoposide - are safe and can be infused without neurological toxicity. The secondary objective is to assess the antitumor activity of these infusions, in the hope that the infusions will yield even more robust treatment responses than those observed in the previous single-agent trials.

The second pilot study, "Infusion of 5-Azacytidine (5-AZA) into the Fourth Ventricle or Resection Cavity in Children with Recurrent Posterior Fossa Ependymoma," is also open for enrollment to patients age 1 to 21.

"5-AZA is a DNA methylation inhibitor that has been infused in non-human primates with no neurological toxicity, while achieving substantial and sustained cerebrospinal fluid (CSF) levels," Dr. Sandberg says. "Recent studies have demonstrated that DNA methylation inhibitors are logical therapeutic candidates for ependymomas originating in the

David Sandberg, MD, and his team are investigating novel therapies for children with fourth ventricular brain tumors to avoid systemic toxicity.

posterior fossa. Our goals are to establish the safety of direct administration of 5-AZA into the fourth ventricle and also hopefully demonstrate the clinical efficacy of these infusions."

Both clinical trials build on two previous recent trials conducted at Children's Memorial Hermann Hospital and UTHealth, in which Dr. Sandberg demonstrated that repeated infusions of methotrexate into the fourth ventricle are well tolerated and do not cause new neurological deficits or other serious adverse events. "We have also demonstrated that some patients, all of whom had recurred despite surgery, radiation and chemotherapy, have a response to treatment with decreased tumor burden after the infusions," he says.

Patients enrolled in the studies will undergo surgical placement of a ventricular catheter into the fourth ventricle or posterior fossa resection cavity with simultaneous surgical resection of recurrent tumor as indicated. Safety will be assessed through serial neurological examinations and MRI scans, and

treatment response will be assessed via MRI scans of the brain and spine as well as lumbar punctures to assess CSF cytology.

Each of the two studies will enroll an estimated 10 patients. For questions about the studies or more information about enrollment, contact Bangning Yu, MD, PhD, by email at bangning.yu@uth.tmc.edu or call 713.500.7363.

Designing a Regenerative Patch for In-utero Spina Bifida Repair

Fewer than half the patients who undergo in-utero myelomeningocele repair with a patch show improvement in spinal cord function. With an R21 grant from the National Institute of Child Health and Human Development, maternal-fetal medicine specialist Ramesha Papanna, MD, MPH, along with Stephen Fletcher, DO, pediatric neurosurgeon, and his research team aim to gain greater understanding of the lack of complete benefit after fetal surgery. They hope to improve the neurological outcomes of affected children through regenerative repair of the defect site using a patch made of donated cryopreserved human umbilical cord. The researchers also have received approval from the Federal Drug Administration for an Investigational New Drug (IND) application for future study, and have been granted Regenerative Medicine Advanced Therapy (RMAT) and Orphan Drug designations by the FDA.



RAMESHA PAPANNA, MD, MPH

Assistant Professor, Department of Obstetrics, Gynecology and Reproductive Sciences
McGovern Medical School at UTHealth

“Our overall objective in the R21 study is to determine, in an animal model, whether the use of cryopreserved human umbilical cord for in-utero spina bifida repair reduces inflammation and scar formation at the repair site and improves outcomes,” says Dr. Papanna, who holds a faculty appointment in the department of Obstetrics, Gynecology and Reproductive

Sciences at McGovern Medical School at UTHealth and is affiliated with The Fetal Center at Children’s Memorial Hermann Hospital and UT Physicians. “Using a surgical animal model, we are comparing the patch made of human umbilical cord to conventionally used methods in an effort to reduce scar formation and improve the function of the spinal cord at and below the defect site.

The researchers’ hypothesis is based on preliminary data formulated in Dr. Papanna’s laboratory. FDA approved for ophthalmological diseases and chronic diabetic ulcers, human umbilical cord (HUC) has an active component – heavy chain hyaluronic acid/pentraxin 3 – that demonstrates anti-inflammatory and anti-scarring properties. The idea was conceptualized in collaboration with Scheffer C.G. Tseng, MD, PhD, chief scientific officer and co-founder of TissueTech™, Inc. in Miami. Dr. Tseng is a world-renowned surgeon in ocular surface reconstruction and a widely published physician scientist with more than 300 peer-reviewed clinical and scientific papers. He pioneers limbal stem cell transplantation and developed and commercialized the CryoTek® process to preserve the natural wound healing properties of amniotic membrane for ocular surface reconstruction.

“We believe HUC has the potential to improve the quality of life of children and families with spina bifida, the most common neural tube defect in the United States,” Dr. Papanna says. “Characterized by the incomplete development of the coverings of the brain, spinal cord or meninges, the defect can result in paralysis, urinary or bowel dysfunction and mental retardation.”

Dr. Papanna’s current research builds on his laboratory’s experience with cryopreserved human umbilical cord for in-utero spina bifida repair. His findings were published in multiple leading peer-reviewed journals including *Obstetrics & Gynecology*,¹ the journal of the American Congress of Obstetricians and Gynecologists; *Ultrasound in Obstetrics*

and *Gynecology*;² *Prenatal Diagnosis*;³ and *Journal of Perinatology*.⁴

Made of the donated outer layer of the umbilical cord of healthy newborns, the patch has been used for repairs performed at Children’s Memorial Hermann Hospital. “The regenerative properties of heavy chain hyaluronic acid/pentraxin 3 allows the local tissue to grow in at the repair site instead of healing by scar formation as occurs with traditional repair methods,” says Dr. Papanna, lead author of the article. “This decrease in scar formation may help improve spinal cord function further and reduce the need for future surgeries to remove the effects of the scar tissue on the spinal cord.”

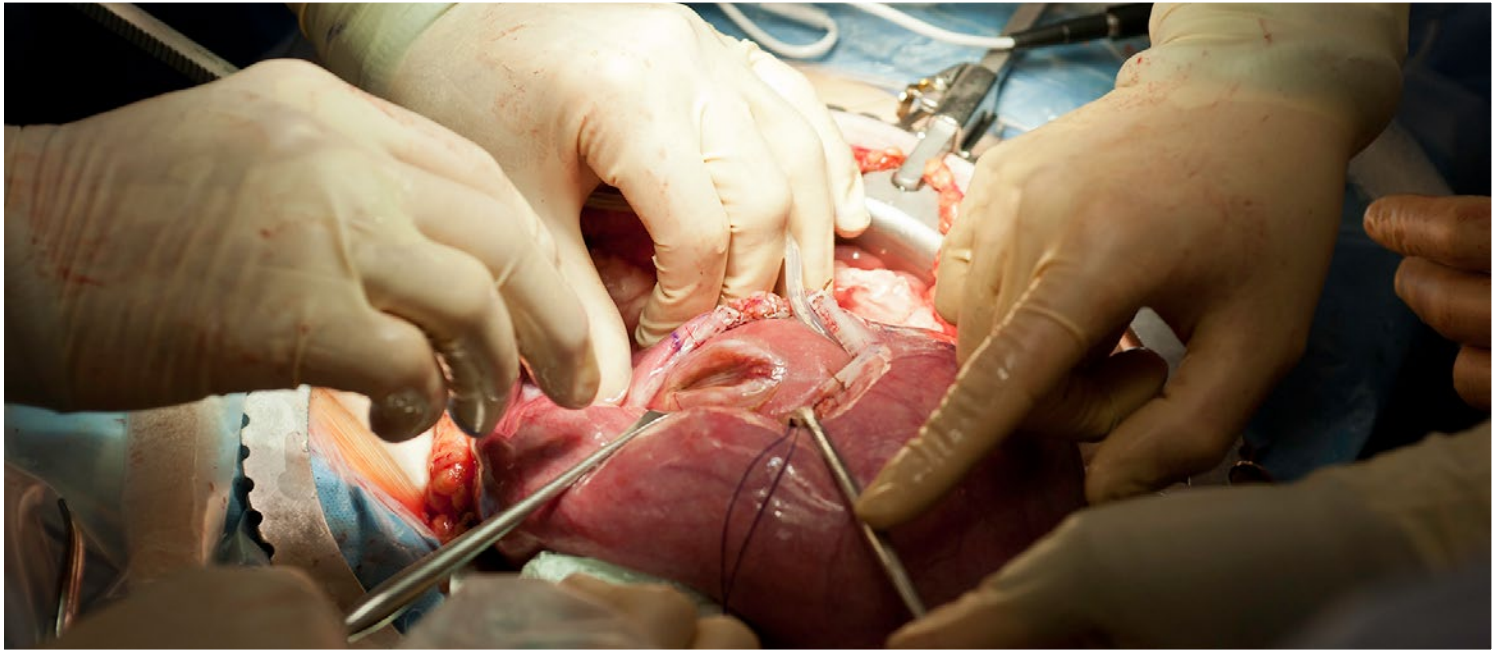
In 2011, a landmark clinical trial – the Management of Myelomeningocele Study (MOMS) sponsored by the National Institutes of Health – found that if a fetus underwent in-utero surgery to close the defect, the serious complications associated with spina bifida could be reversed or lessened. In cases where the defect was too large to close with the fetus’s existing skin, a patch was necessary. But in some cases, scar tissue may cause adherence of the patch to the underlying spinal cord, which could result in a loss of neurologic function as the child ages. Further surgery is often needed to remove the scar tissue.

“The use of this patch for fetal repair heralds a new era for fetal spina bifida repair,” says Kenneth Moise, MD, co-author, professor and co-director of The Fetal Center at Children’s Memorial Hermann Hospital and McGovern Medical School. “For the first time, a bioscaffold has been successfully employed to allow the fetus to heal itself. The implications for the future of a minimally invasive approach to fetal spina bifida repair and even neonatal spina bifida repair are enormous.”



KENNETH MOISE, MD

Co-Director, The Fetal Center
Professor, Department of Obstetrics, Gynecology and Reproductive Sciences
McGovern Medical School at UTHealth



The researchers have performed three human cases of in-utero spina bifida repair of severe defects, skin defects that are too large for primary closure, all of which were approved by the FDA under Expanded Access Use, by the Fetal Therapy Board of The Fetal Center at Children's Memorial Hermann Hospital and by the UTHealth Institutional Review Board prior to the surgeries. The patients underwent fetal surgery performed by Stephen Fletcher, DO, co-author, associate professor in the McGovern Medical School Department of Pediatric Surgery and a pediatric neurosurgeon affiliated with Mischer Neuroscience Institute at Memorial Hermann-Texas Medical Center and Children's Memorial Hermann Hospital, and KuoJen Tsao, MD, associate professor and The Children's Fund Distinguished Professor in Pediatric Surgery and co-director of The Fetal Center. Dr. Moise and Dr. Papanna also participated in the surgeries. The children are between 18 months to 28 months of age. One baby had a ventriculoperitoneal shunt placement for borderline ventriculomegaly. All three have good lower-extremity motor and sensory function and have been able to stand and walk with support. The initial two cases were published in *Obstetrics & Gynecology*,¹ and the long-term outcomes are pending.



STEPHEN FLETCHER, DO

Associate Professor, Division of Pediatric Neurosurgery
McGovern Medical School at UTHealth



KUOJEN TSAO, MD

Co-Director, The Fetal Center
Professor, Department of Pediatric Surgery
McGovern Medical School at UTHealth

The clinical cases were the culmination of eight years of research after Dr. Papanna and article co-author Lovepreet K. Mann, MBBS, an instructor in the department of Obstetrics, Gynecology and Reproductive Sciences at UTHealth, began brainstorming ideas about possible patch materials. Their research led them to their co-author Scheffer C.G. Tseng, who was using human amniotic membrane and umbilical cord - donated by mothers of healthy infants - to repair corneas.



LOVEPREET K. MANN, MBBS

Instructor, Department of Obstetrics, Gynecology and Reproductive Sciences
McGovern Medical School at UTHealth

"This patch acts as a scaffold, which is watertight and allows native tissue to regenerate in an organized manner, and

Researchers at UTHealth hope to improve in-utero spina bifida repair using a patch made of cryopreserved human umbilical cord.

also has anti-scarring, anti-inflammatory properties," Dr. Mann says. "Preventing the scarring could prevent tethering, which can in turn prevent further damage to the cord."

The patch was first tested in animal models by a team of researchers that included Dr. Papanna, Dr. Mann, Dr. Fletcher and Dr. Moise. In 2011, after the national MOMS trial for fetal surgery was ended early because of positive results, physicians at McGovern Medical School and The Fetal Center were the first in Texas to perform the newly approved surgery, and the first time that cryopreserved human umbilical cord was used for this purpose in the world. Since then the team has performed more than 65 fetal surgeries to treat spina bifida.

Dr. Mann says the research team is focusing on further improving outcomes by pushing the boundaries of fetal wound healing and improving outcomes through regenerative repair. "If we can make a small change and improve the quality of life for the child, that will mean we really accomplished something," she says.

The team has since completed two additional surgeries using the patch. In

one case two layered patches were used – deeper tissue layer and skin layer – and the child is now two years old. Dr. Fletcher has used the new patch in surgeries to untether the spinal cord of children who had previous spina bifida surgery.

National Institutes of Health R21 grants encourage exploratory/developmental research by providing support for the early, conceptual stages of project development. “Our approach is innovative in that it departs from the status quo by using the naturally occurring regenerative properties of HUC to improve healing of in-utero spina bifida repair to reduce long-term neurological deficits,” Dr. Papanna says. “We expect the research to vertically advance and expand the benefits of in-utero repair of spina bifida, including facilitating minimally invasive repair to reduce maternal risks associated with the large uterine incision needed for the current approach. Ultimately, the new knowledge we’re gaining has the potential to lead to newer approaches to the treatment of other congenital anatomical birth defects, such as cleft lip/palate, gastroschisis and diaphragmatic hernia.”

The FDA’s IND approval of the patch for in-utero repair of severe spina bifida, and granting of the Orphan Drug and Regenerative Medicine Advanced Therapy designations, provide the opportunity to test the patch in large groups of patients for its efficacy at a shorter duration of time. The researchers are collaborating with three other North American Fetal Treatment Centers – including the University of Colorado at Denver, Mayo Clinic in Rochester, and Minneapolis Children’s Hospital in Minneapolis – to conduct the study in the next three to five years.

Currently, the research team members are working to find ways to encourage the skin to heal inside the uterus and different ways to deploy the patch over the defect site through less invasive means. “We’ve made progress at an incredibly rapid pace,” Dr. Papanna says. “Taking

an idea from the lab to the human use typically takes about a decade. We’ve been able to reduce that time by more than half. We have a good system in place with strong collaborators, all of whom have track records of success in their fields.”

Research collaborators from other disciplines and institutions include Ponnada Narayana, PhD, professor of radiology, and Rajan Patel, MD, assistant professor of radiology at UTHealth; and Raymond

The movement to fetoscopic repair at Children’s Memorial Hermann Hospital will take place after the physicians have completed a comprehensive training program on a laboratory model, thereby avoiding some of the problems that have been reported at other centers. An ongoing assessment of the physiology of the fetus in the womb, the amniotic fluid environment and best surgical practice will insure the highest quality and outcomes for this new field of medicine.

“WE EXPECT THE RESEARCH TO VERTICALLY ADVANCE AND EXPAND THE BENEFITS OF IN-UTERO REPAIR OF SPINA BIFIDA, INCLUDING FACILITATING MINIMALLY INVASIVE REPAIR TO REDUCE MATERNAL RISKS ASSOCIATED WITH THE LARGE UTERINE INCISION NEEDED FOR THE CURRENT APPROACH. ULTIMATELY, THE NEW KNOWLEDGE WE’RE GAINING HAS THE POTENTIAL TO LEAD TO NEWER APPROACHES TO THE TREATMENT OF OTHER CONGENITAL ANATOMICAL BIRTH DEFECTS.”

Grill, PhD, associate professor of neurobiology and anatomical sciences at the University of Mississippi.

“Dr. Papanna is a workhorse for UTHealth and our efforts to further our research in a very competitive market,” Dr. Stephen Fletcher says. “We see patients who come from across the country, and when I ask them why they travel so far, they say it’s because of the research under way at UTHealth. We are leaders in the field. We’re moving forward slowly and deliberately to answer every question and avoid the failures that have occurred in other programs.”

“We do that because Children’s Memorial Hermann Hospital is about patients. If they’re not here, we’re not here,” Dr. Papanna says. “What we’ve done to date in showing real benefit to children is just the tip of the iceberg. There’s still plenty of work to do. We want all babies who undergo the fetal surgery to be able to walk at age three. Our goal is to take the percentage from less than half today to 100 percent.”

¹Papanna R, Fletcher S, Moise KJ Jr, Mann LK, Tseng SCG. Cryopreserved Human Umbilical Cord for In Utero Myelomeningocele Repair. *Obstet Gynecol.* 2016 Aug;128(2):325-30.

²Papanna R, Moise Jr. KJ, Mann LK, Fletcher S, Schniederjan R, Bhattacharjee M, Stewart RJ, Kaur S, Prabhu S, Tseng SCG. Cryopreserved Human Umbilical Cord Patch for In-utero Spina Bifida Repair. *Ultrasound Obstet Gynecol.* 2016 Feb;47(2):168-76.

³Papanna R, Mann LK, Snowise S, Morales Y, Prabhu SP, Tseng SCG, Grill R, Fletcher S, Moise Jr. KJ. Neurological Outcomes after Human Umbilical Cord Patch for In-utero Spina Bifida Repair in a Sheep Model. *AJP Rep.* 2016 Jul;6(3):e309-17.

⁴Snowise S, Mann LK, Lyu M, Morales Y, Moise Jr KJ, Fletcher S, Grill R, Tseng SCG, Papanna R. Cryopreserved Human Umbilical Cord (HUC) vs. Biocellulose Film (BCF) for Antenatal Spina Bifida Repair. *Prenat Diagn.* 2017 May;37(5):473-481.

NEWS of NOTE

Dr. David Sandberg Receives Ian's Friends Foundation Award



IAN'S FRIENDS FOUNDATION

David I. Sandberg, MD, FAANS, FACS, FAAP, has received funding from Ian's Friends Foundation (IFF), a nonprofit organization that provides support for innovative research designed to find a cure for pediatric brain tumors. Dr. Sandberg will use the \$125,000 grant to support his two current pilot trials: "A Combination Intraventricular Chemotherapy Pilot Study," investigating methotrexate and etoposide infusions into the fourth ventricle in children with recurrent posterior fossa brain tumors, and "Infusion of 5-Azacytidine (5-AZA) into the Fourth Ventricle or Resection Cavity in Children with Recurrent Posterior Fossa Ependymoma," which aims to establish the safety of direct administration of 5-AZA into the fourth ventricle and demonstrate its clinical efficacy.



DAVID SANDBERG, MD, FAANS, FACS, FAAP
 Director, Pediatric Neurosurgery; Professor and Chief, Division of Pediatric Neurosurgery; Dr. Marnie Rose Professorship in Pediatric Neurosurgery
 McGovern Medical School at UTHealth

Dr. Sandberg holds the Dr. Marnie Rose Professorship in Pediatric Neurosurgery at McGovern Medical School at UTHealth and is director of pediatric neurosurgery at Children's Memorial Hermann Hospital, Mischer Neuroscience Institute and the medical school. His major research interests focus on novel means of delivering

therapeutic agents to the brain for treatment of childhood brain tumors.

IFF partners with or supports research labs at leading hospitals and universities across the country focused on the development of new therapeutic methodologies and treatments for pediatric brain tumors. The foundation also works to bring public awareness to the severity of pediatric brain tumors and raises funds to sponsor research. In making the recent awards, the IFF invited 39 investigators from around the country to submit proposals and asked the scientists to vote on the three projects they considered most worthy of funding. Each of the selected investigators received a \$125,000 grant.

"This award is very important to me as a physician and researcher," Dr. Sandberg says. "The funding is critical to help support our clinical trials. Moreover, it's a great honor to be recognized by leaders in our field. The presentations at this meeting were extraordinary, and many were from leading clinicians and scientists from our country's finest institutions. The fact that these leaders chose to fund our clinical trials makes me even more hopeful that our novel approach to treating children with brain tumors has great promise."

Dr. Manish N. Shah Named a Texas Super Doctors Rising Star



MANISH N. SHAH, MD
 Director, Pediatric Spasticity and Epilepsy Surgery
 Assistant Professor, Division of Pediatric Neurosurgery
 McGovern Medical School at UTHealth

Manish N. Shah, MD, a pediatric neurosurgeon affiliated with Children's Memorial Hermann Hospital and Mischer Neuroscience Institute at Memorial Hermann-Texas Medical Center, has been selected by his peers as a Super Doctors® Rising Star in Texas for the second consecutive year. Following an extensive independent nomination and research process, the results were published in the June 2018 issue of *Texas Monthly* magazine.

Dr. Shah directs the Texas Comprehensive Spasticity Center at Children's Memorial Hermann Hospital, the Mischer Neuroscience Institute and McGovern Medical School at UTHealth. He is also director of pediatric spasticity and epilepsy surgery and runs a laboratory where researchers use advanced neuroimaging techniques to investigate basic brain function in children.

"I am proud to be recognized along with so many respected individuals in the Greater Houston medical community," Dr. Shah says. "Helping children achieve a better quality of life in the face of debilitating disease is a privilege and a reward in itself."

Dr. Shah is an assistant professor in the department of Pediatric Neurosurgery at the McGovern Medical School and the leading neurosurgeon in the area for selective dorsal rhizotomy. He is fellowship trained in pediatric neurosurgery with special expertise in the surgical management of spasticity and dystonia in children, and performs selective dorsal rhizotomies and baclofen pump placement using advanced techniques. He is also a specialist in pediatric epilepsy, craniofacial surgery and craniocervical spine surgery.

Report on the 2018 Run for the Rose

Children's Memorial Hermann Hospital and Mischer Neuroscience Institute at Memorial Hermann-Texas Medical Center were proud sponsors of the 16th Anniversary Run for the Rose, held Sunday, April 8, 2018, at NRG Park in Houston. Participants, ranging in age from 2 months to 100 years, included patients, family members and supporters committed to raising awareness and funds supporting brain cancer research at The University of Texas MD Anderson Cancer Center, Children's Memorial Hermann Hospital and McGovern Medical School at UTHealth.

The run is sponsored annually by the Dr. Marnie Rose Foundation, which has supported brain cancer research and




Run for the Rose participants represented Children's Memorial Hermann Hospital and Mischer Neuroscience Institute.

pediatric health initiatives in Houston since 2003. In 2017, the Foundation made a donation of \$85,000 - funds raised through the Run for the Rose, the Brain Power 5K in Austin and memorials and tributes made throughout the year - to Children's Memorial Hermann Hospital. David I. Sandberg, MD, FAANS, FACS, FAAP, holds the Dr. Marnie Rose Professorship in Pediatric Neurosurgery that the Foundation sponsors. To date, the Dr. Marnie Rose Foundation has given more than \$5.7 million to Children's Memorial Hermann Hospital, MD Anderson Cancer Center and McGovern Medical School. At UTHealth, funds support cutting-edge research and treatment for children with brain tumors, a cause close to Dr. Marnie Rose's heart.

Other race-day activities included a Family 1K and a post-race party at NRG Park for all participants. Awards were given to male and female 5K participants who finished first, as well as the top three male and female finishers in specific-age categories. Children received medals.

Memorial Hermann and UTHealth Welcome Dr. Bangning Yu



BANGNING YU, RN, PhD

Clinical Trial Program Manager, Division of Neurosurgery
Department of Pediatric Surgery
McGovern Medical School at UTHealth

Bangning Yu, RN, PhD, has joined the staff of Children's Memorial Hermann Hospital and Mischer Neuroscience Institute as clinical trial program manager serving the department of Pediatric Surgery, division of Neurosurgery at McGovern Medical School at UTHealth.

Dr. Yu received his bachelor's degree in medicine at Central South University in Changsha, Hunan, China, followed by a master's degree and a PhD in clinical pharmacology at the same institution. He earned his associate degree in nursing at Azure College in Sebring, Florida.

Dr. Yu has strong clinical research experience in oncology, transplant, gastroenterology, and Phase I, II and III clinical trials, as well as extensive clinical experience both in hospital and clinic settings. Prior to joining Memorial Hermann and UTHealth, he served as a

research nurse clinician at the Rutgers University Cancer Institute of New Jersey in New Brunswick. He is a co-author of articles published in multiple peer-reviewed journals.

AANS/CNS Pediatric Neurological Surgery Section Meeting Held in Houston



CNS



American Association of Neurological Surgeons

The 46th Annual Meeting of the American Association of Neurological Surgeons/Congress of Neurological Surgeons (AANS/CNS) section on Pediatric

Neurological Surgery was held Nov. 28 to Dec. 1, 2017, in Houston.

The meeting was co-chaired by David I. Sandberg, MD, FACS, FAANS, FAAP, who welcomed hundreds of physicians from across the United States and provided an overview of pediatric brain tumors. Manish N. Shah, MD, co-directed the Stereotactic Electrode Implantation and Laser Ablation for Epilepsy Course, and Stephen A. Fletcher, DO, gave an update on trauma and on fetal surgery for spina bifida. Dr. Sandberg is professor and director of pediatric neurosurgery and holds the Dr. Marnie Rose Professorship in Pediatric Neurosurgery in the department of Pediatric Surgery and Vivian L. Smith Department of Neurosurgery at McGovern Medical School at UTHealth. Dr. Shah directs the Pediatric Epilepsy Surgery Program and the Texas Comprehensive Spasticity Center at Children's Memorial Hermann Hospital, the Mischer Neuroscience Institute and McGovern Medical School, where he is an assistant professor in the department of Pediatric Surgery. Dr. Fletcher is an associate professor in the division of Pediatric Neurosurgery.



DAVID SANDBERG, MD, FAANS, FACS, FAAP
Director, Pediatric Neurosurgery; Professor and Chief, Division of Pediatric Neurosurgery; Dr. Marnie Rose Professorship in Pediatric Neurosurgery
McGovern Medical School at UTHealth

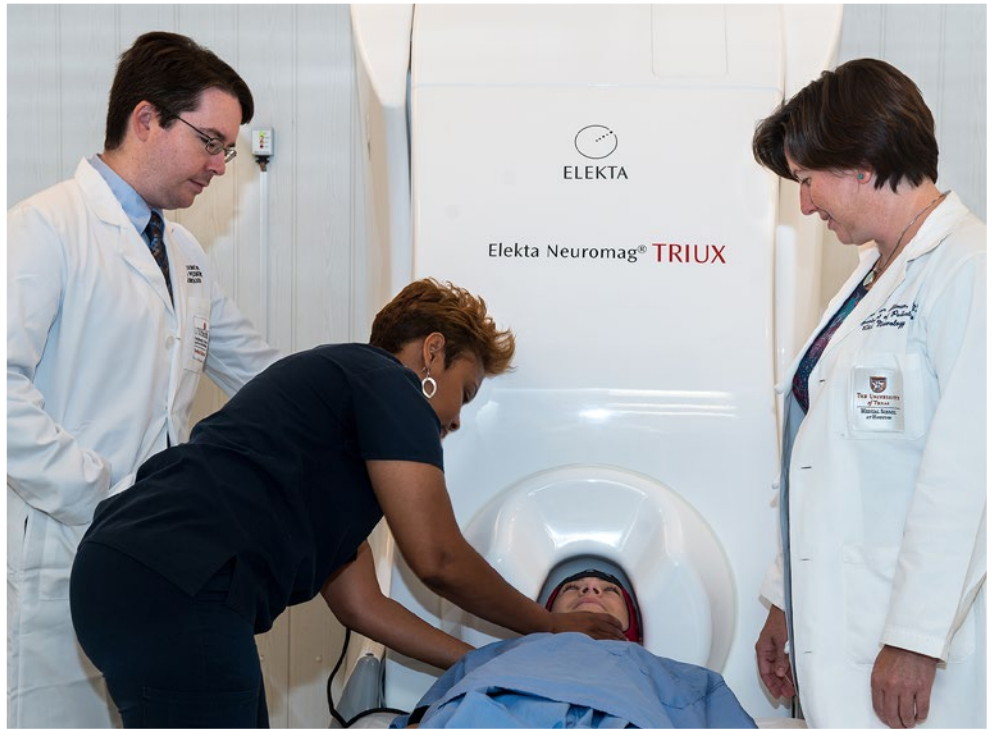

MANISH N. SHAH, MD
Director, Pediatric Spasticity and Epilepsy Surgery
Assistant Professor, Division of Pediatric Neurosurgery
McGovern Medical School at UTHealth



STEPHEN FLETCHER, DO
Associate Professor, Division of Pediatric Neurosurgery
McGovern Medical School at UTHealth

The AANS is a scientific and educational association focused on advancing the specialty of neurological surgery. The organization has more than 8,000 members worldwide.



Children's Memorial Hermann Hospital and Mischer Neuroscience Institute Sponsor Pediatric Epilepsy Seminar

The Pediatric Epilepsy Patient Education Seminar was held on March 3 at the Denton A. Cooley, MD, and Ralph C. Cooley, DDS, University Life Center at The University of Texas Health Science Center at Houston (UTHealth).

Pediatric neurologist Gretchen Von Allmen, MD, and pediatric neurosurgeon Manish N. Shah, MD, presented on symptoms and diagnosis of epilepsy in pediatric patients as well as treatment options available at Children's Memorial Hermann Hospital.

Patients and families were invited to learn about the Level IV comprehensive pediatric epilepsy center, recognized by the National Association of Epilepsy Centers. The pediatric epileptologists affiliated with Children's Memorial Hermann Hospital specialize in comprehensive epilepsy care at the Epilepsy Monitoring Unit (EMU). Before creating an individualized treatment plan, it's necessary to determine the type or types of seizures the patient is experiencing. The EMU is a large, family-friendly unit with

Dr. Gretchen Von Allmen and Dr. Manish Shah are among a handful of researchers using MEG to map brain networks before and after epilepsy treatment.

specialized equipment to help identify the type of seizures and the brain location from which they originate, and to aid in the delivery of an individualized epilepsy treatment plan.



GRETCHEN VON ALLMEN, MD
Director, Pediatric Epilepsy Program; Medical Director, Memorial Hermann Pediatric Epilepsy Monitoring Unit; Associate Professor, Division of Pediatric Neurology
McGovern Medical School at UTHealth



MANISH N. SHAH, MD
Director, Pediatric Spasticity and Epilepsy Surgery
Assistant Professor, Division of Pediatric Neurosurgery
McGovern Medical School at UTHealth

SELECTED PUBLICATIONS

January through December 2017

Al Hammoud R, Nayas SL, Murphy JR, Heresi GP, Butler IJ, Perez N. *Angiostrongylus Cantonensis* Meningitis and Myelitis in Texas. *Emerg Infect Dis*. 2017;23(6):1037-38.

Bagić AI, Bowyer SM, Kirsch HE, Funke ME, Burgess RC; ACMEGS Position Statement Committee. American Clinical MEG Society (ACMEGS) Position Statement #2: The Value of Magnetoencephalography (MEG)/Magnetic Source Imaging (MSI) in Noninvasive Presurgical Mapping of Eloquent Cortices of Patients Preparing for Surgical Interventions. *Journal of Clinical Neurophysiology*. 2017 Jan 5. doi: 10.1097/WNP.0000000000000366. [Epub ahead of print]

*Epi4K consortium, **EPGP Investigators**. Ultra-rare genetic variation in common epilepsies: a case-control sequencing study. *Lancet Neurology*. 2017; 16: 135-143.

Gu JL, Johnson A, Kerr M, Moise KJ Jr, Bebbington MW, Pedroza C, Sandberg DI. Correlating Prenatal Imaging Findings of Fetal Ventriculomegaly with the Need for Surgical Intervention in the First 3 Months after Birth. *Pediatr Neurosurg*. 2017;52(1):20-25. Epub 2016 Sep 28.

Martinez CI, Fletcher S, Shah MN, Kerr ML, Sandberg DI. Survey of Techniques Utilized to Access Ventricular Shunts and Reservoirs. *Pediatr Neurosurg*. 2017 June 3. doi: 10.1159/0004744948. Epub ahead of print.

Mattioli F, Schaefer E, Magee A, Mark P, Mancini GM, Dieterich K, Von Allmen G, Alders M, Coutton C, van Slegtenhorst M, Vieville G, Engelen M, Cobben JM, Juusola J, Pujol A, Mandel JL, Piton A. Mutations in Histone Acetylase Modifier BRPF1 Cause an Autosomal-Dominant Form of Intellectual Disability with Associated Ptosis. *Am J Hum Genet*. 2017;100(1):105-116.

Numan MT, Kamdar A, Young J, Butler IJ. Autologous Adipose Stem Cell Therapy for Autonomic Nervous System Dysfunction in Two Young Patients. *Stem Cells Dev*. 2017;26(6):391-393.

Patel RP, Sitton CW, Ketonen LM, Hou P, Johnson JM, Romo S, Fletcher S, Shah MN, Kerr M, Zaky W, Rytting ME, Khatua S, Sandberg DI. Phase-contrast cerebrospinal fluid flow magnetic resonance imaging in qualitative evaluation of patency of CSF flow pathways prior to infusion of chemotherapeutic and other agents into the fourth ventricle. *Childs Nerv Syst*. 2017 Nov 23. doi: 10.1007/s00381-017-3669-6. Epub ahead of print.

Posey JP, Martinez R, Lankford JE, Lupski JR, Numan MT, Butler IJ. Dominant Transmission Observed in Adolescents and Families With Orthostatic Intolerance. *Pediatr Neurol*. 2017;66:53-58.1

Qualmann KJ, Spaeth CG, Myers MF, Horn PS, Holland K, Mangano FT, Greiner HM. Pediatric Epilepsy Surgery: The Prognostic Value of Central Nervous System Comorbidities in Patients and Their Families. *Journal of Child Neurology*. 2017 Apr;32(5):467-74.

**EPGP Investigators: Bassel Abou-Khalil, Brian K. Alldredge, Dina Amrom, Eva Andermann, Frederick Andermann, Jocelyn F. Bautista, Samuel F. Berkovic, Judith Bluvstein, Alex Boro, Gregory D. Cascino, Damian Consalvo, Patricia Crumrine, Orrin Devinsky, Dennis Dlugos, Michael P. Epstein, Miguel Fiol, Nathan B. Fountain, Jacqueline French, Catharine Freyer, Daniel Friedman, Eric B. Geller, Tracy Glauser, Simon Glynn, Kevin Haas, Sheryl R Haut, Jean Hayward, Sandra L. Helmers, Sucheta Joshi, Andres Kanner, Heidi E. Kirsch, Robert C. Knowlton, Eric H. Kossoff, Rachel Kuperman, Ruben Kuzniecky, Daniel H. Lowenstein, Paul V. Motika, Edward J. Novotny, Ruth Ottman, Juliann M. Paolicchi, Jack M. Parent, Kristen Park, Annapurna Poduri, Lynette G. Sadleir, Ingrid E. Scheffer, Renee A. Shellhaas, Elliott H. Sherr, Jerry J. Shih, Shlomo Shinnar, Rani K. Singh, Joseph Sirven, Michael C. Smith, Joseph Sullivan, Liu Lin Thio, Anu Venkat, Eileen P.G. Vining, Gretchen K. Von Allmen, Judith L. Weisenberg, Peter Widdess-Walsh and Melodie R. Winawer.*

Memorial Hermann Health System
7737 Southwest Freeway
Houston, TX 77074

childrens.memorialhermann.org/neuro
832.325.7242

Nonprofit Org.
U.S. POSTAGE
PAID
Permit No. 3156
Houston, TX