

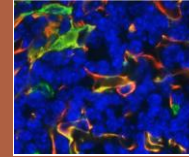


# Under the Scope

Newsletter for the Department of Pathology and Laboratory Medicine  
McGovern Medical School at UTHealth, Houston, Texas  
January – March, 2021



## Pathology in the COVID-19 era: the DPALM Autopsy Service

L. Maximilian Buja, MD, Bihong Zhao, MD, PhD, Michelle McDonald, DO, and Noah Reilly, DO

COVID-19 has presented many challenges for society and medicine in general and our department in particular. Early in the pandemic, clinicians were perplexed by the myriad of manifestations of seriously ill COVID-19 patients. It was clear that autopsy studies would be needed to understand the underlying pathology. However, legitimate concerns were raised about the safety of performing cases. This was heightened by initially confusing recommendations from OSHA and CDC. In DPALM, a collective effort was mounted to understand the parameters for safe environmental working conditions in our morgues at MHH-TMC and Ben Taub hospitals as well as optimal personal protective equipment (PPE) for our autopsy residents, faculty and staff. The result was that we kept our autopsy service operational when many autopsy services around the country shut down. We started performing autopsies on COVID-19 patients in early 2020, and we also established a collaboration to study cases performed at the Harris County Medical Examiner's Office. To date, we have performed close to 40 autopsies on hospitalized COVID-19 cases.



We published one of the first autopsy studies based on our early experience. We documented that the pathological basis for the acute respiratory distress syndrome (ARDS) seen in severely ill COVID-19 patients is a severe form of diffuse alveolar damage (DAD) with prominent hyaline membranes, proliferation of type II pneumocytes with cytopathic changes, moderate lymphohistiocytic inflammatory infiltrates and frequent microvascular and macrovascular thrombosis. The finding of thrombotic vasculopathy, confirmed by others, had been important in establishing prompt anticoagulation in the management of COVID-19 patients. We also found a variety of changes in other organs documenting that COVID-19 is a systemic disease. This included focal single cell cardiomyocyte injury without overt myocarditis as the basis for the troponin elevation seen as a maker of adverse outcome in COVID-19 patients. We also have documented the patient's demographics and frequent occurrence of comorbidities: obesity, cardiomegaly, history of hypertension, diabetes, chronic renal disease and chronic lung diseases.

Another ongoing project is the evaluation of different immunohistochemical antibodies for SAR-CoV-2. So far we have analyzed lung slides from 14 autopsy cases. Our preliminary results indicate viable viral particles are largely cleared from the tissue prior to the development of the advanced stages of DAD and ongoing immune reaction is the primary driver of continued damage. The different antibodies have produced uniform results across this first sample.

*COVID-19 related articles published by Department of pathology and Laboratory Medicine ([Click here](#))*

## Neuropathology in COVID-19 autopsy examinations – the DPALM experience

Michelle McDonald, DO, and Meenakshi B. Bhattacharjee, MD, FRCPath, FCAP

To date, we performed autopsies in 40 patients with COVID-19 infection, 17 of which included brain dissection. We herein report the salient gross and microscopic neuropathologic findings in our institutional cohort. **Patient characteristics:** 8 males and 9 females, age range: 36 to 71 y (mean=57.4, SD=11.37). 10 were Hispanic, 4 Caucasian, 2 African-American, and 1 Asian. Body mass index range from 20.4 to 48.8 kg/m<sup>2</sup> (average=32.2, SD=7.14). Five patients were overweight (BMI: 25 to <30), and nine were obese (BMI ≥30). Common comorbidities were hypertension (n= 8, 47%), diabetes mellitus type 2 (n= 7, 41%), cerebrovascular accident (n= 4, 24%), hyperlipidemia (n= 4, 24%), cancer (n= 3, 18%), dementia (n= 2, 12%),

chronic obstructive pulmonary disease (n= 2, 12%), and coronary artery disease (n=2, 12%). Other individual comorbidities were variable. All patients were tested for SARS-CoV-2 by nasopharyngeal swab. Hospitalization ranged from 1 to 69 days (average=26 days, SD=20). 15 patients were ventilated, 11 received dexamethasone, 9 received convalescent plasma, 8 received Remdesivir, and 2 received hydroxychloroquine, and 4 patients received ECMO. **Neuropathological findings:** Fixed brain weights ranged from 1050 to 1500 g (mean=1300, SD=136.5). 8 patients had cerebral edema, 8 had cerebrovascular atherosclerosis, 5 had herniation, 4 had atrophy with ex-vacuo hydrocephalus, and 3 had hemorrhages. Microscopically, intravascular fibrin thrombi in small and medium vessels, petechiae, microscopic and larger acute/subacute infarcts, ring and ball hemorrhages and infarcts, and acute hypoxic-ischemic changes were common findings. Chronic changes included hypertensive vasculopathy, remote large vessel strokes, Alzheimer disease, metabolic gliosis, and other pathologies specific to individual patients. Notably, the olfactory bulbs and tracts showed no pathologic changes. **Conclusion:** Large and small vessel cerebral infarcts and hemorrhages in patients that would not be expected based upon their age, and comorbidities suggest an underlying vasculopathy or coagulopathy.

### **COVID-19 testing strategies during pandemic – the DPALM monumental effort during testing times**

The DPALM has been making tremendous effort on patient care, clinical research and education during COVID pandemic. During the early stages, the UT Pathology Lab implemented SARS-CoV-2 testing to meet the community need. With the help of leadership and dedicated team of Gustavo Ayala MD, Yu Bai MD, PhD, Leomar Y. Ballester MD, PhD, Catherine Scott HT (ASCP) CLLM (AACC), Phoebe Mai MBA, MT (ASCP) and Mauli Shah MS, MB (ASCP), DPALM implemented two SARS-CoV-2 Assays; one assay using the Panther® System from Hologic and another assay using the BioFire FilmArray Torch Instrument System.

The Aptima® SARS-CoV-2 assay is a nucleic acid amplification *in-vitro* diagnostic test intended for the qualitative detection of RNA from SARS-CoV-2 isolated and purified from upper respiratory specimens (such as nasopharyngeal, nasal, mid-turbinate and oropharyngeal swabs, and nasopharyngeal wash/aspirate or nasal aspirates). The Aptima SARS-CoV-2 assay combines the technologies of target capture, transcription mediated amplification, and dual kinetic assay. Linking with an automatic nucleic acid extraction instrument, this FDA authorized high-throughput molecular testing system is able to process over 5000 samples continuously over 24 hours which has allowed us to complete a test run in 4-6 hours. The BioFire® FilmArray® 2.0 System offers a molecular viral antigen detection in a single-use cartridge. It conducts multiple test steps with little space or instrumentation requirement. This system has allowed us to provide STAT (1-hour) results for a select number of patients.

With both molecular testing methods covering the urgent needs and huge demands, DPALM has been working around-the-clock to perform the assays and provide data as quick as possible helping the clinics at the Houston metropolitan and the surrounding variable communities, such as sport teams, working places, etc. for COVID management. To date, approximately 42,000 samples have been tested for the presence of SARS-CoV-2 at UT Pathology with an average turn-around-time of less than 24 hours. With a team effort and collaboration, UT Pathology has provided COVID molecular assays with multiple convenient sample pick-up locations, reliable high-throughput assay and rapid turn-around-time for the medical society around Houston area. DPALM also work with the local health department for data collection to monitor the infection trend in the city. This information has been useful for epidemiology analysis and public health decision-making.

### **Research Effort in Applying Digital Pathology & Deep Learning to Pathologic Diagnosis**

Andy Nguyen, MD was invited to present "*Automated Lymphoma Diagnosis with Whole Slide Imaging and Deep Learning*" at the *Digital Pathology & Artificial Intelligence Congress: USA, Nov 19-20, 2020*. This presentation describes our research to use Deep Learning to build a diagnostic model for four categories of lymphoma with whole slide imaging. Our results showed excellent diagnostic accuracy at 95% for image-by-image prediction and at 100% for set-by-set prediction. This preliminary study provided a proof of concept for incorporating automated lymphoma diagnostic screen into future pathology workflow to augment the pathologists' productivity.

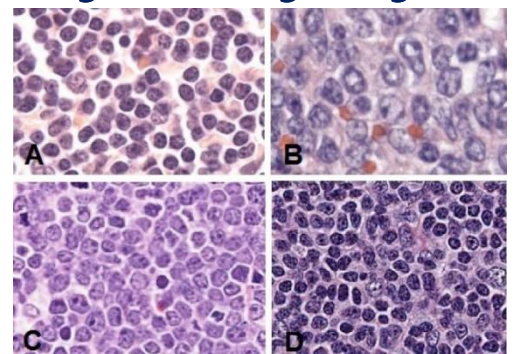


Figure 1. Representative WSI sections for four diagnostic categories in our deep learning system: (A) Benign lymph nodes, (B) Diffuse large B-cell lymphoma, (C) Burkitt lymphoma, (D) Small lymphocytic lymphoma.

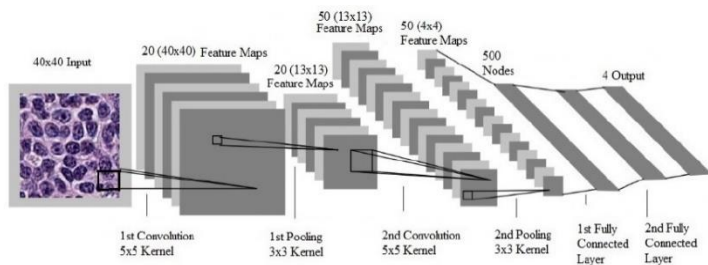


Figure 2. Processing pipeline of a convolutional neural network for the detection of visual categories in images.

Part of above effort had been presented by **El Achi H**, at Pathology Visions, Oct 6-8, 2019 as "*Deep Learning and Automated Diagnosis of Lymphoma with Whole Slide Imaging*". Co-authors: Belousova B, Chen L, Wahed A, Wang I, Hu Z, Kanaan Z, Rios A, Nguyen A. **Award: Best Abstract in Pathology Visions.**

Current departmental effort focuses on "*Application of Deep Learning to predict positive breast cancer metastasis from whole slide imaging of Sentinel Lymph Nodes*". We

are using Motic scanner for H&E slides of breast cancer cases from Memorial Hermann and LBJ hospitals. Our Deep Learning platform is based on: software written in Python, TensorFlow, Keras; and hardware with Graphics Processing Unit for parallel matrix processing. The study group includes Sun H, Zhang S, Wang XI, Ding J, Saluja K and Nguyen A.

## Resident Round-Up

Compiled by Amanda Hermann, MD and Karan Saluja, MBBS, MD

Resident research has been very active this year, and while the COVID-19 pandemic has put a damper on in-person networking at academic conferences, residents have continued to pursue interesting research topics and clinical case presentations on the state and national level. Here is a sample of some of the engaging research projects which have gained attention at recent pathology conferences here in Texas and around the country.

- Diagnostic and prognostic roles of EBER ISH in patients with HIV-associated aggressive non-Hodgkin lymphomas. **Mai B**, Wang W, Shuai W, Wang X, Chen L, Wahed A, Nguyen A, Hu S, Hu Z. USCAP 2021; Platform presentation (to be presented at the annual meeting March 13-18).
- COVID-19 autopsy findings: A case series from Houston, TX. **McDonald M**; Zhang S; Buja LM; Zhao B; USCAP Annual Meeting 2021; Poster presentation.
- The optimal approach of EBUS-FNA Rapid On-site Evaluation (ROSE): A five-year experience from a large academic medical center; **Elzamly S**, Al-Habib A, Thomas-Ogunniyi J, Liu J, Zhu H, Buryanek J, Zhang S; USCAP Annual Meeting 2021; Poster presentation.
- Dermatology of soft parts; when a rare entity becomes even more complicated. **Ali Y**, Covinsky M; American Society of Dermatopathology, 57th Annual Meeting (Nov 2020); Platform presentation.
- CXCR4 as a therapeutic target in angiosarcoma. **Ghosh A**, Brown RE, Bull JM, Elzamly S, Buryanek J; American Association for Cancer Research, Annual meeting 2021; E-poster.
- A challenging case of a myeloid sarcoma misdiagnosed as high-grade B-cell lymphoma; **Mai B**, Herrmann A, Elzamly S, Wahed A, Nguyen A, Chen L; ASCP 2020; Poster presentation: **Award: Blue Ribbon Finalist in Educational Category**
- Prometastatic CXCR4 and histone methyltransferase EZH2 are upregulated in *SMARCB1/INI1*-deficient and *TP53*-mutated poorly-differentiated chordoma; **Murzabdillaeva A**, Elzamly S, Jafri SH, Rowe J, Brown R, Buryanek J ASCP 2020; Poster presentation: **Award: Blue Ribbon Finalist in Educational Category**
- Bleed to breathe: Venous-venous extracorporeal membrane oxygenation anticoagulation management in the setting of COVID-19-associated hyper-coagulopathy; **Herrmann A**, Allison P, Chen A, Guillory B, Akkanti B, Tint H; AABB Annual Meeting 2020; Platform presentation; **Award: Outstanding abstract award for trainee**
- Cost savings and patient safety analysis of mixed age red cell exchange in sickle cell patients: A single treatment center experience; **Herrmann A**, Tint H, Lelenwa L, Hobbs R, Bai Y; AABB Annual Meeting 2020, Poster presentation
- The involvement of bilateral parotid lymphoepithelial cysts as the initial presentation of T-cell prolymphocytic leukemia with t(X;14)(q28;q11); **Ghosh A**, Chen L, Aakash FNU, Lin M, Nguyen ND, Wahed A, Hu Z; Texas Society of Pathologists (TSP) Annual Meeting 2021; **Award: 1st place, Case Report Poster Presentation**
- Disarranged coagulation and hemostasis with COVID-19 infection: One single community hospital experience of 62 patients; **Mai B**, Huddin J, Hu Z; TSP Annual Meeting 2021; **Award: 2nd Place for Best Investigative Poster Presentation**
- A death caused by left ventricular assist device thrombosis in a COVID-19 patient; **Wang H**, Zhao B; TSP Annual Meeting 2021, **Award: 2nd Place in Trainee Case Report Division**
- Central Granular Cell Odontogenic Tumor (CGCOT) of the mandible: an uncommon entity; **Savariya B**, Elzamly S, Saluja K; TSP Annual Meeting 2021; Poster presentation.
- Incidental colonic masses and cytomegalovirus infection in a treatment-naive chronic lymphocytic leukemia (CLL) patient without GI symptoms; **Elzamly S**, Shitawi M, Taha H, Ghosh A, Everett J; TSP Annual Meeting 2021; Poster presentation.
- Relapsed plasma cell myeloma presenting as 'plasmacytoma' with amyloid deposition in the head and neck; **Wang W**, Chen L; TSP Annual Meeting 2021; Poster presentation.

- Mass-forming neoplastic extramedullary hematopoiesis mimics myeloid sarcoma in a patient with chronic phase chronic myeloid leukemia; **Hermann A**, El Achi H, Hu Z; TSP Annual Meeting 2021; Poster presentation.
- Evolution of acute undifferentiated leukemia to mixed phenotype acute leukemia: An interesting case report; **Ali H**, Mai B, Nguyen A; TSP Annual Meeting 2021; Poster presentation.
- Low-grade well differentiated ampulla adenocarcinoma synchronous with retroperitoneal dedifferentiated liposarcoma; **Li R**, Thomas-Ogunniyi J, Liu J, Zhang S; TSP Annual Meeting 2021; Poster presentation.
- A case of HIV associated primary bone marrow Hodgkin's lymphoma with secondary hemophagocytic lymphohistiocytosis; **Moosvi AM**, El Achi H, Hu Z, Wang Xi; TSP Annual Meeting 2021; Poster presentation.
- A patient with concurrent promyelocytic leukemia and COVID-19 infection: A coagulopathic catastrophe; **Shirai S**, Mai B, Nguyen A, Wahed A, Chen L, Hu Z; TSP Annual Meeting 2021; Poster presentation.
- Hürthle cell follicular carcinoma of the thyroid gland evolving to anaplastic carcinoma in a patient with history of scrofula; **Shitawi A**, Taha H, Elzamy S, Savariya B, Sun H; TSP Annual Meeting 2021; Poster presentation.
- Neuroendocrine carcinoma of cervix; **Taha H**, Shitawi M, Elzamy S, Savariya B, Guo T. TSP Annual Meeting 2021; Poster presentation.

## ***116 DPALM publications listed on PubMed in 2020***

As part of our efforts to publicize the scholarly work of the department, PubMed searches of all of our faculty were made at the National Center for Biotechnology Information (NCBI) website (<https://www.ncbi.nlm.nih.gov/>). This search resulted in the identification of 116 published articles, which are listed at ([click here](#)). This compilation, although impressive, does not include additional publications, such as book chapters and other articles not accessible through NCBI. We will continue efforts to make publications by our faculty, residents, other trainees and staff readily available to DPALM members and the public.

## ***Blood Bank/Transfusion Medicine Fellowship Program approved by ACGME***

In January 2021, the Accreditation Council for Graduate Medical Education (ACGME) approved a new fellowship program in DPALM for Blood Bank and Transfusion Medicine. The initial fellowship will begin on July 1, 2021. Anyone interested in applying for a fellowship position should contact Dr. Hlaing Tint at [Hlaing.Tint@uth.tmc.edu](mailto:Hlaing.Tint@uth.tmc.edu).

## ***Announcing DPALM's new Committee for Diversity and Inclusion***

The inaugural departmental Committee for Diversity and Inclusion was formed in the fall of 2020 and consists of faculty, staff, and trainees from within our department that are committed to upholding the mission of fostering a diverse, culturally rich, and inclusive educational environment through intentional, organized, and united efforts. The committee meets bimonthly and invites any interested members of the Pathology Department to participate. The committee is led by Dr. Jamie M. Everett who serves as the Departmental Vice Chair of Diversity and Inclusion. Those interested in joining the committee can reach out to her directly via email ([jamie.m.everett@uth.tmc.edu](mailto:jamie.m.everett@uth.tmc.edu)). Look for future activities and endeavors organized by this committee to celebrate and support our uniquely diverse and culturally-rich department!

## ***Dr. Jamie Everett receives sponsorship to attend the AAMC Leadership Development Seminar for Women in Medicine and Science***



Assistant Professor and Director of GI and Liver Pathology, Jamie M. Everett, MD received a scholarship sponsored by the Office of Faculty Affairs and the Office of Diversity and Inclusion in addition to support from the Department of Pathology and Laboratory Medicine, to attend the Association of American Medical Colleges (AAMC) Leadership Development Seminar for Women in Medicine and Science, February 23-25, 2021. The program is designed for women physicians and scientists in the early stages of leadership positions. The seminar is aimed to help participants gain insights into the realities of building a career in academic medicine and science, grow their professional network, and explore various paths to leadership. Dr. Everett was elated to receive their support and would highly recommend attendance to any female faculty interested in expanding their leadership skills and network. [Click here to learn more information.](#)

## *Dr. Amanda Hermann receives award to attend Pathologists Leadership Summit*



DPALM Resident Amanda Hermann, MD received the College of American Pathologists (CAP) Foundation Leadership Development Award, which will support her attendance of the Pathologists Leadership Summit. This 'hybrid' Summit will include both in-person and virtual formats and will be held May 1-4, 2021 in Washington, DC. The purpose of this program is to "introduce pathology residents to the specialty's issues and leadership opportunities at the institutional, local, state, and national levels," and includes pairing of each resident with a mentor in their area of interest. More information about the Pathologists Leadership Summit and the Leadership Development Award is available at <https://10times.com/pathologists-leadership-summit-washington-dc> and <https://foundation.cap.org/what-we-fund/leadership-development/>

## *Relocation of Pathologists at Lyndon B. Johnson Hospital*

LBJ Pathology Faculty and Anatomic Pathology Residents have permanently moved to the 4<sup>th</sup> floor of LBJ Hospital (4DE-40.002.1-P Suite). Clinical Pathology Residents and Chief of Service offices remain within the LBJ 3<sup>rd</sup> floor laboratory.

---

*Under the Scope*® is published quarterly by the Department of Pathology and Laboratory Medicine of the McGovern Medical School, University of Texas Health Science Center at Houston. Copies of this newsletter and additional information regarding the department and its programs are available at the departmental website, <https://med.uth.edu/pathology/>. Please submit stories for future editions to one of the co-editors listed below. Co-editors: Amanda Hermann ([Amanda.C.Hermann@uth.tmc.edu](mailto:Amanda.C.Hermann@uth.tmc.edu)), Karan Saluja ([Karan.Saluja@uth.tmc.edu](mailto:Karan.Saluja@uth.tmc.edu)), Jamie Everett ([Jamie.M.Everett@uth.tmc.edu](mailto:Jamie.M.Everett@uth.tmc.edu)), and Steven Norris ([Steven.J.Norris@uth.tmc.edu](mailto:Steven.J.Norris@uth.tmc.edu)). Administrative Assistant: Shanequa Bradley ([Shanequa.C.Bradley@uth.tmc.edu](mailto:Shanequa.C.Bradley@uth.tmc.edu)).