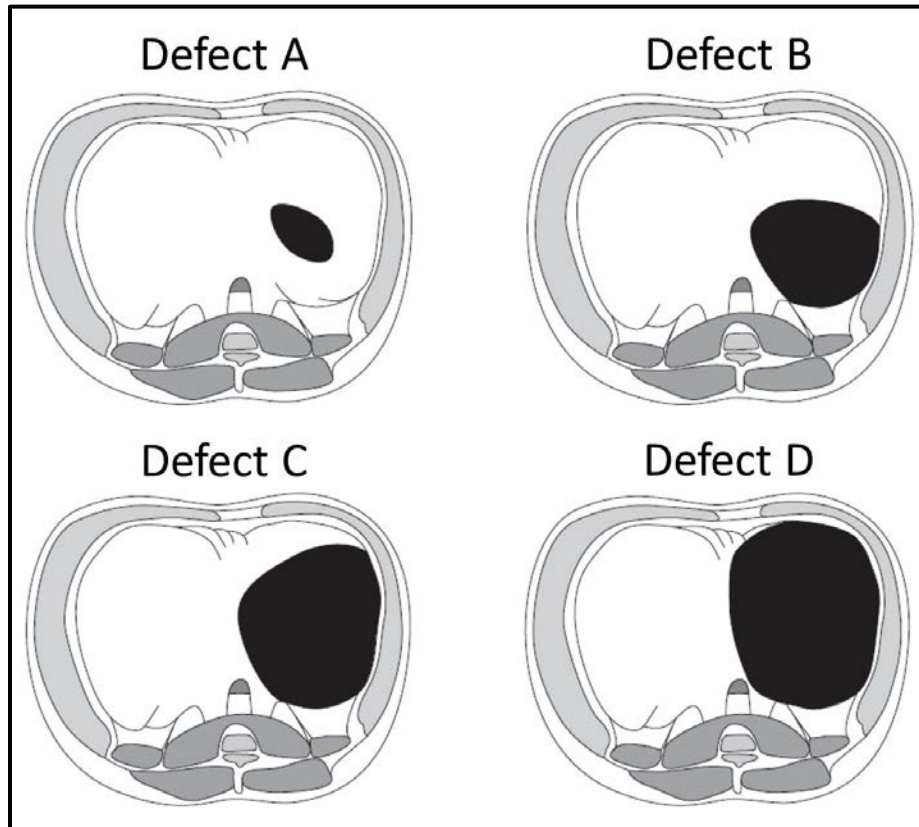


Diaphragm defect descriptions for the CDHSG Staging System



CDH Study Group Staging System. A left diaphragmatic defect is shown as viewed from the peritoneal cavity looking toward the hemi-thorax. Defects are classified as:

“Defect A”: smallest defect, usually “intramuscular” defect with >90% of the hemi-diaphragm present; this defect involves <10% of the circumference of the chest wall

“Defect B”: 50-75% hemi-diaphragm present; this defect involves <50% of the chest wall

“Defect C”: <50% hemi-diaphragm present; this defect involves >50% of the chest wall

“Defect D”: largest defect (previously known as “agenesis”); complete or near complete absence of the diaphragm with <10% hemi-diaphragm present; this defect involves >90% of the chest wall. Surgically, it is an absent posterior rim beyond the spine, absent posterior-lateral rim, and an anterior/anterior-medial rim which is miniscule. As it is truly unusual to have zero tissue at all, this is the CDHSG member consensus. “D” defects should all require a patch (or muscle flap) for repair.

There is no defect diagram for **right-sided defects** so the CDHSG recommends applying the above descriptions and reversing (mirror-image) the diagrams to determine the size of a right-sided defect.