

IR Trauma Embolization

Jose Viramontes

06/24/19

DII RAD 4001 elective

(Assistance from Dr. Jeff Guccione, PGY3)



McGovern
Medical School

History

35 F

MVC with ejection

Hypotensive on scene, GCS 3T, SBP of 50's, and HR of 120's

Chest X-Ray, Pelvic X-ray, FAST performed

Tourniquets on left thigh, Pelvic binder in place

Taken to OR to repair injuries and stop bleeding

Given 28 units of blood

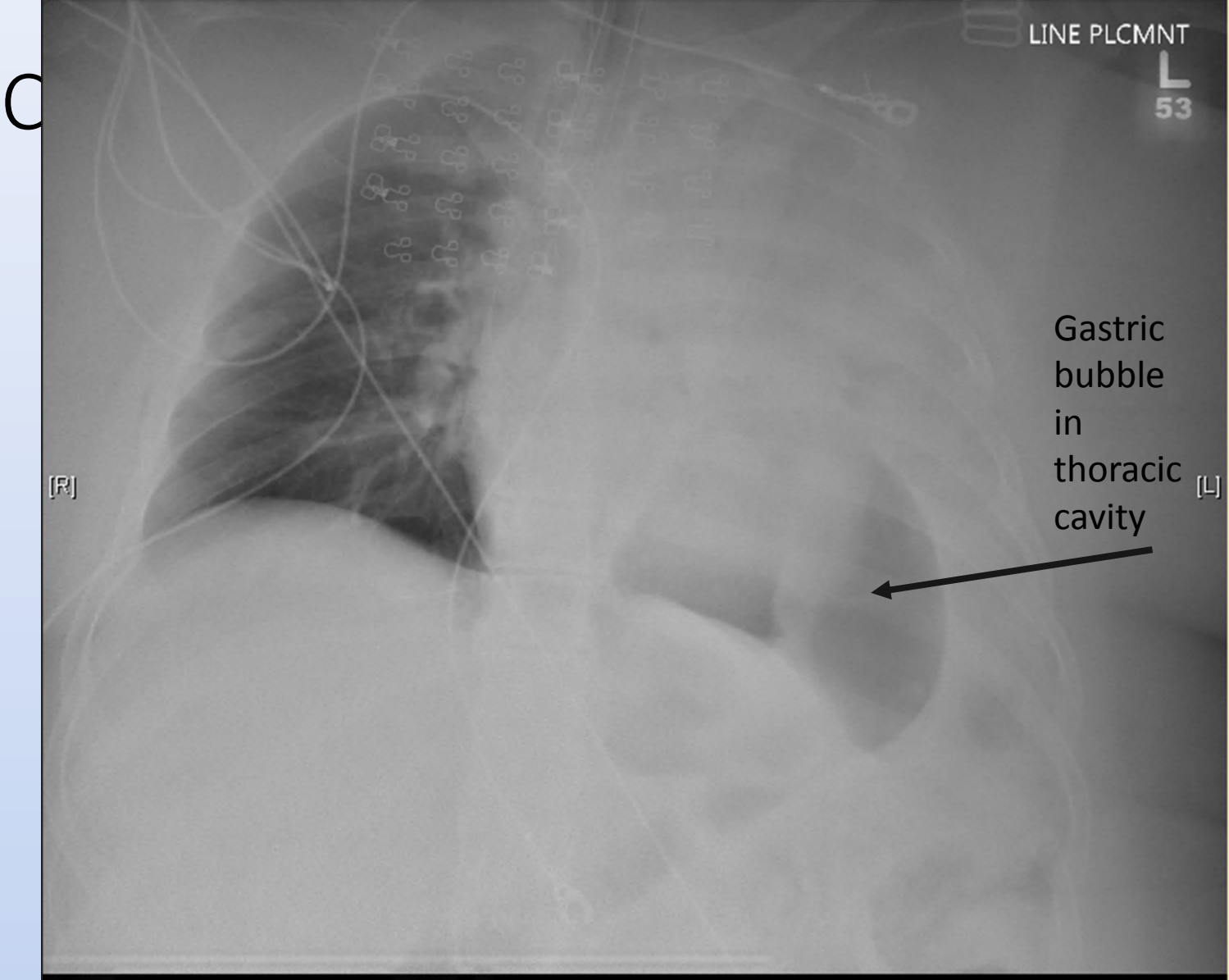
Able to repair ruptured left hemidiaphragm and stop bleeding

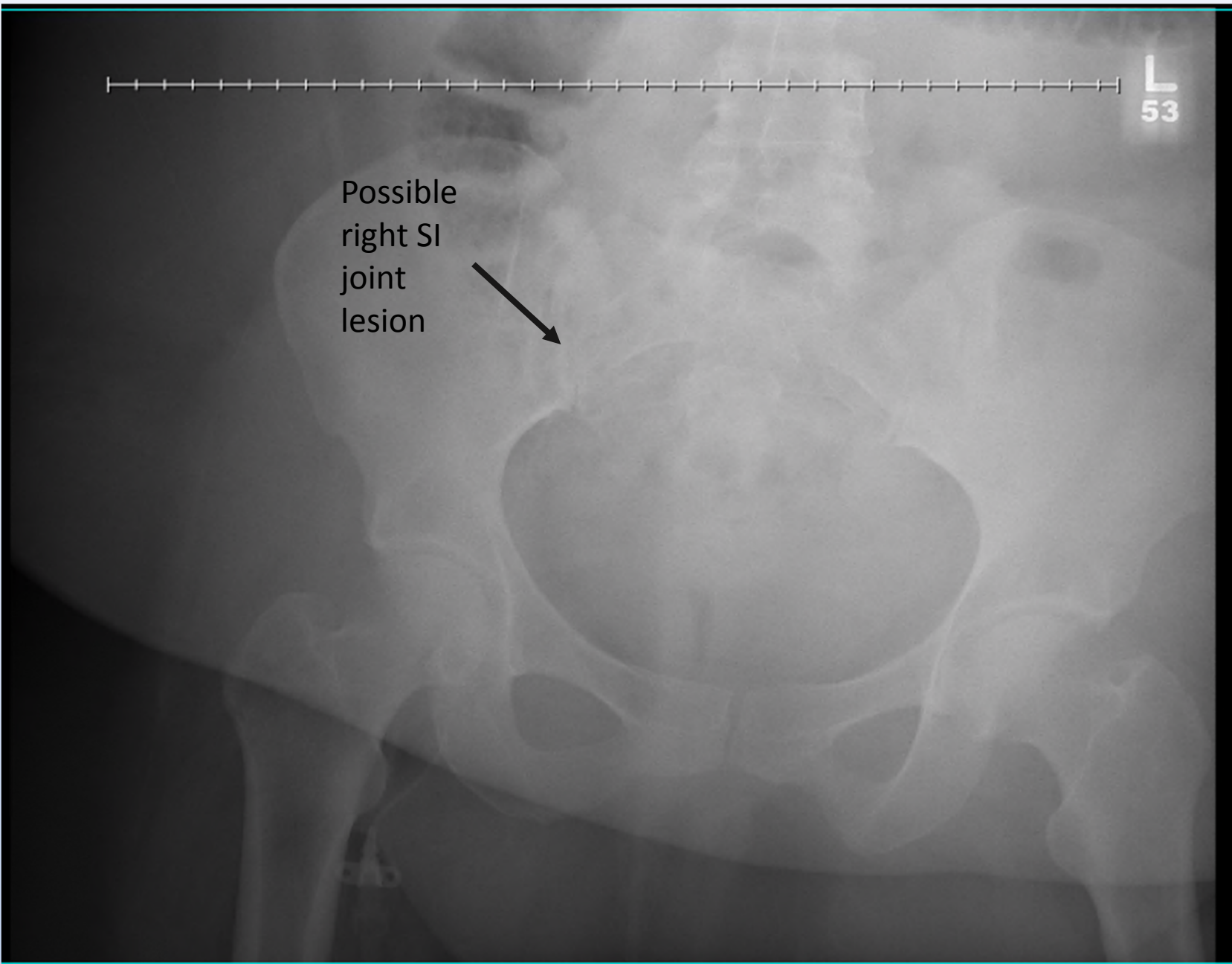
Noted in OR- Ongoing left flank/retroperitoneal or paralumbar bleeding.

Packed with lap sponges in OR and patient sent to IR

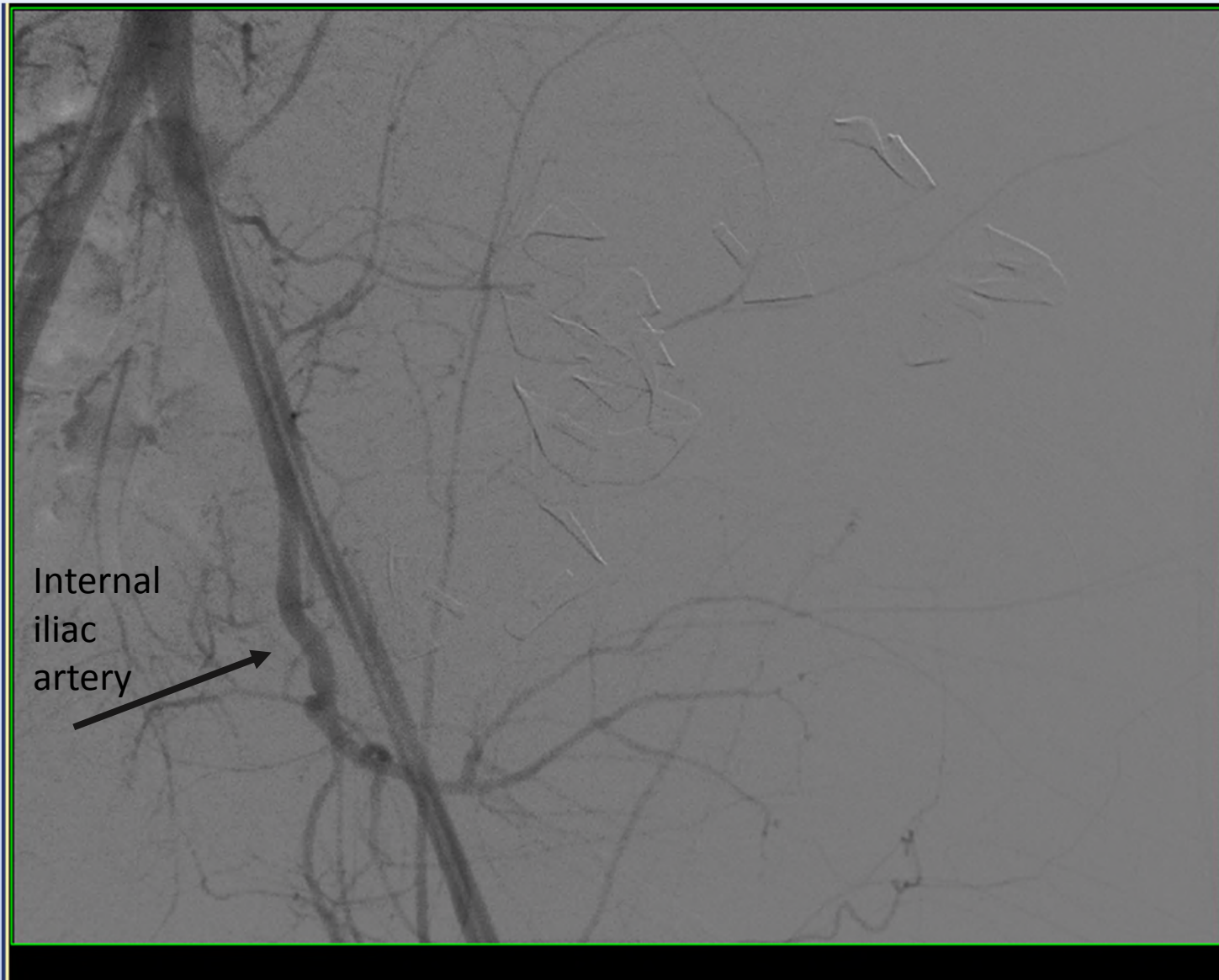
Angiography performed

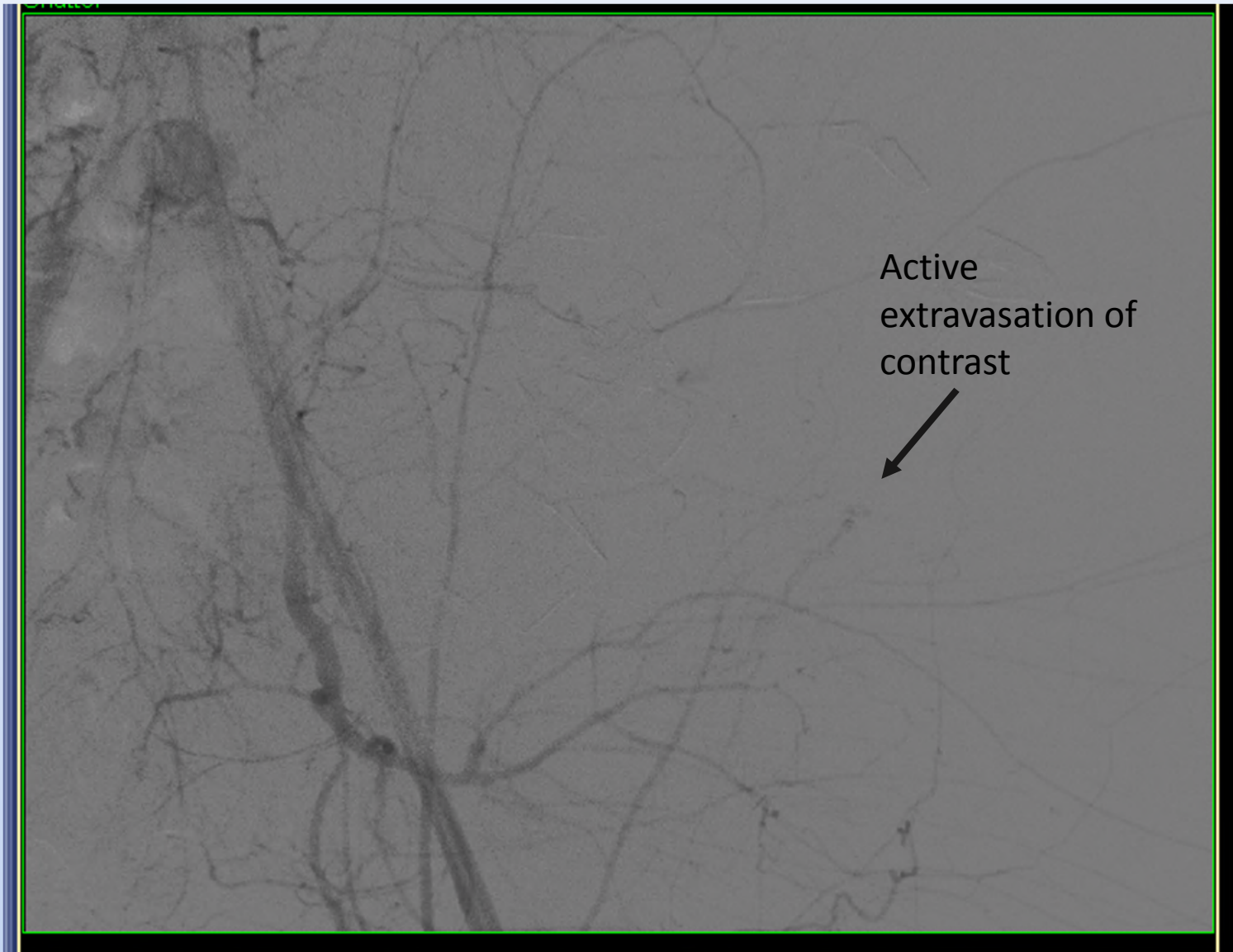
Images






Angiography Pre Embolization



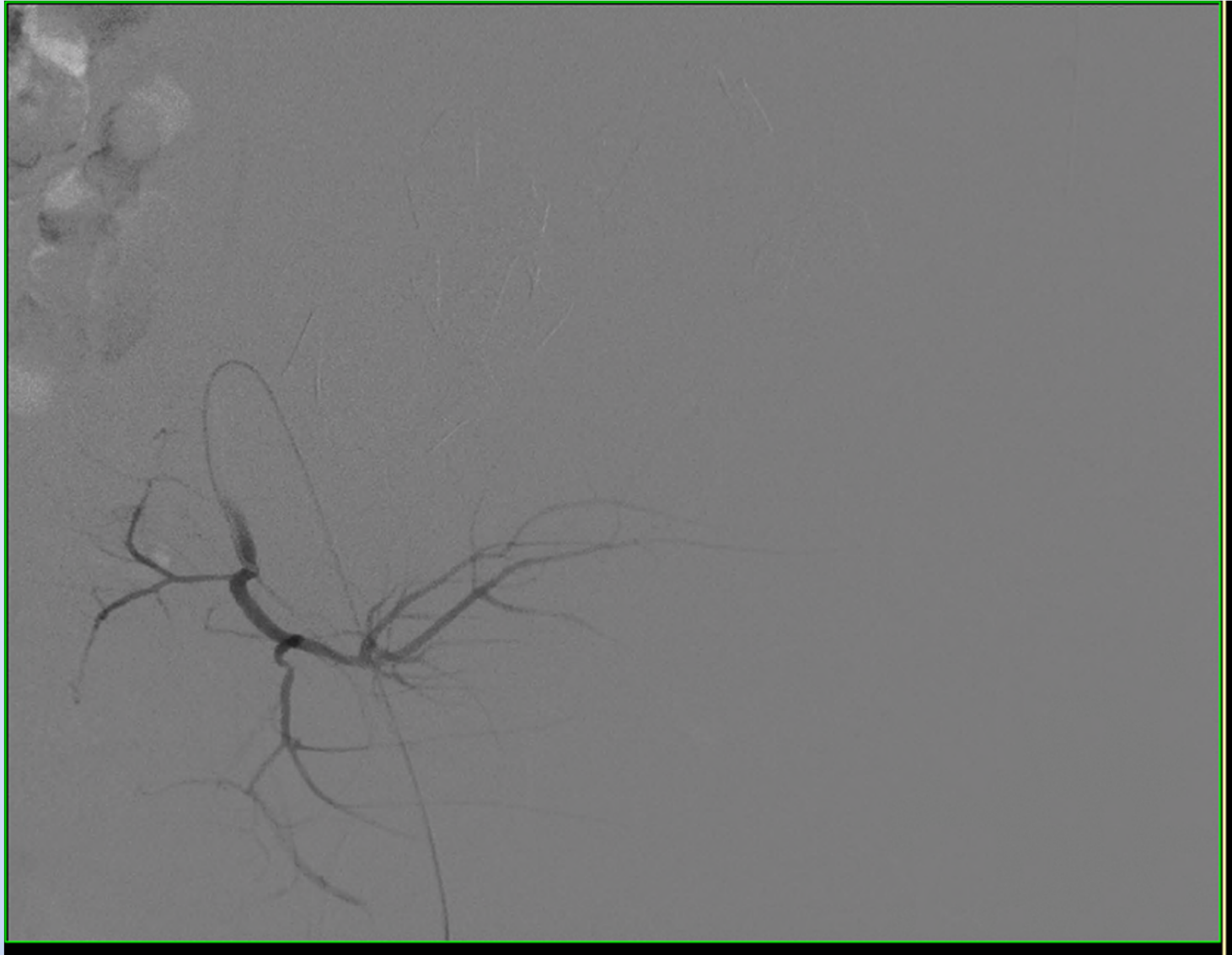


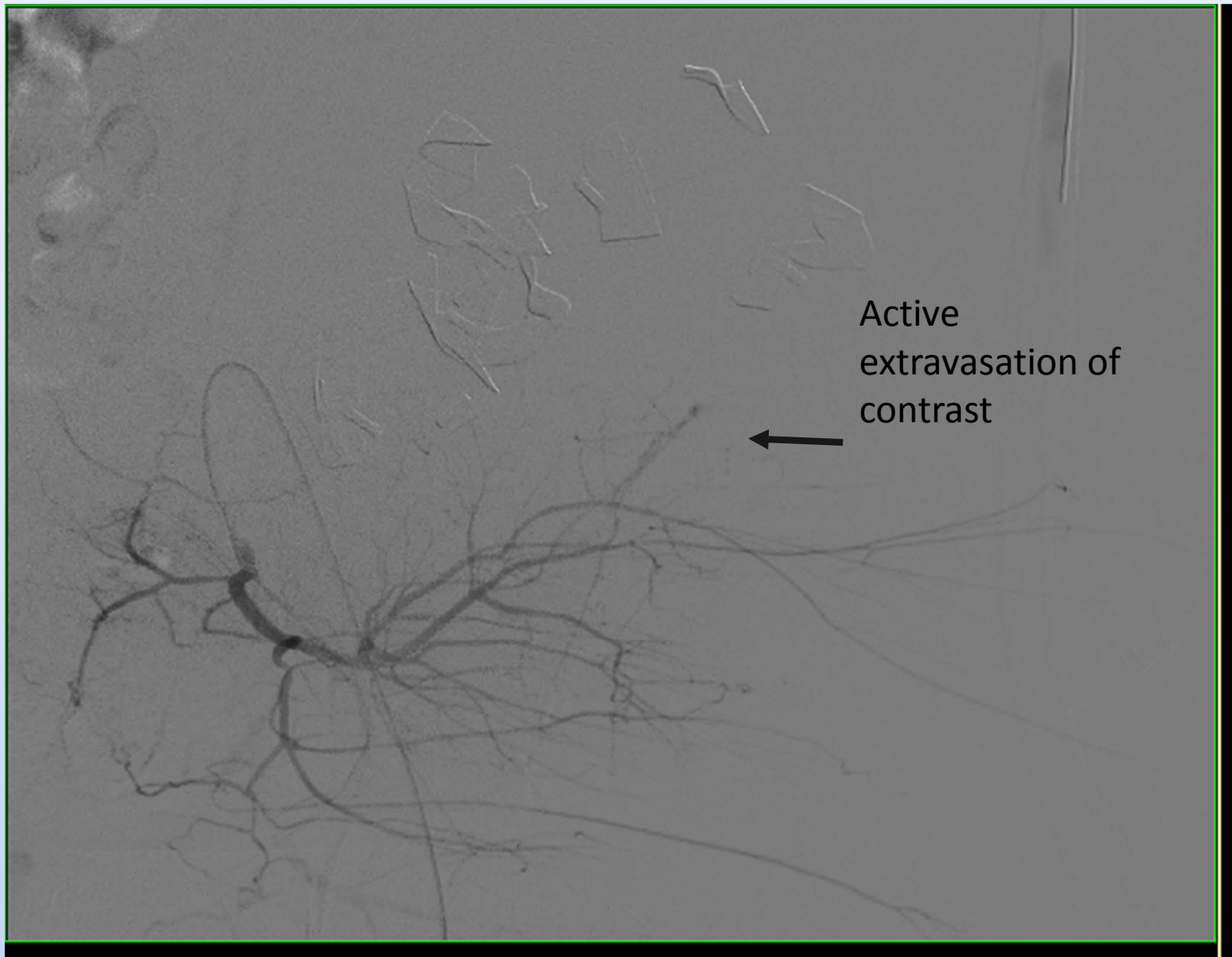


Active
extravasation of
contrast



Angiography Pre Embolization with Internal Iliac Artery Selection





Active
extravasation of
contrast

