

# SALTER HARRIS FRACTURES in CHILDREN

**Kyra Frost**

**11/12/19**

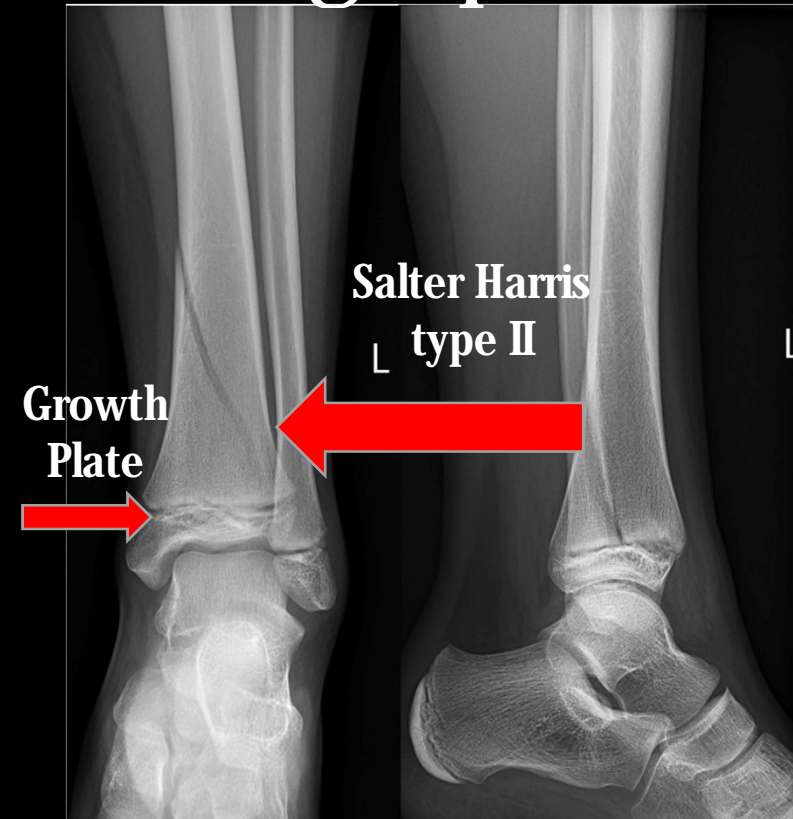
**Diagnostic Radiology RAD 4001**

**Dr. Kumaravel**

# Clinical History salter harris type 2 left tibia

- 10 year old previously healthy boy comes into the Ed with a one day history of pain, swelling, and inability to move his left ankle after falling while playing tag.
- Current Sx:
  - Pain and swelling around the ankle
  - Pain did not improve after taking Ibuprofen and putting ice on the
- Physical exam findings:
  - Vital signs with in normal limits with the exception of mild tachycardia most likely related to pain: T: 99 HR: 110 RR: 15 BP: 118/78 Spo2: 100 % RA
  - Swelling at the left ankle joint and pain with passive ROM
  - Pt was unable to preform active ROM due to pain, and was unable to bear weight on affected left side.
  - Pt had 5+ strength in right lower extremity, DTR were 2+ throughout, and distal dorsalis pedis was 2+ bilaterally on exam
- Work- Up
  - Xray of left, ankle, and foot
  - Xray of right, ankle, and foot for comparison

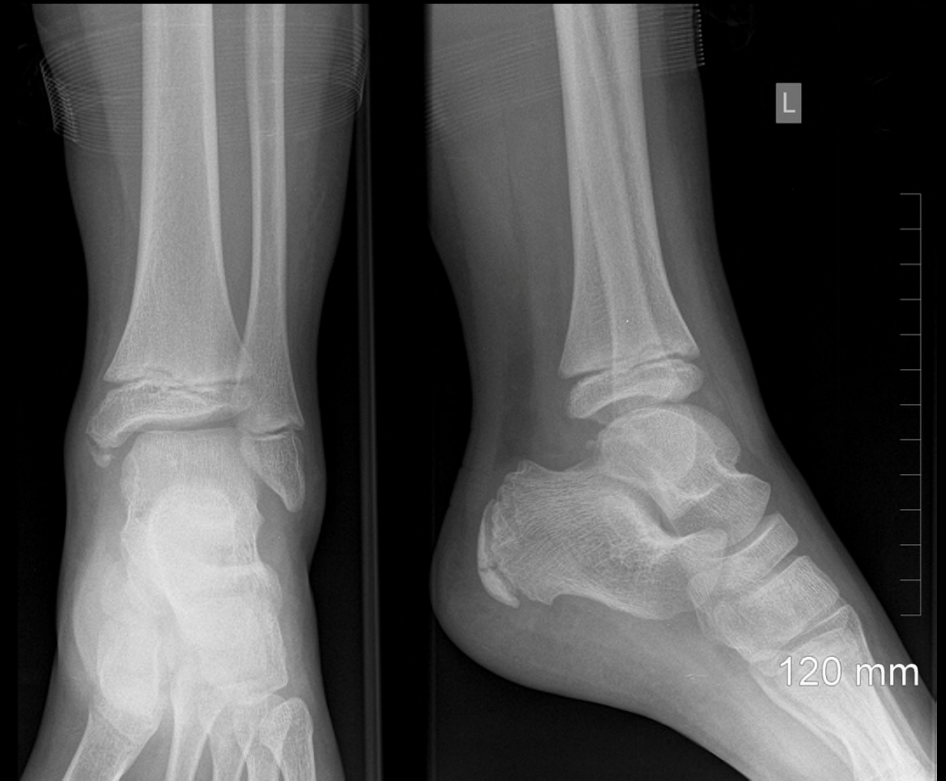# Radiograph of left ankle



- The average cost for an Xray of the foot is:

**50-130\$**

Our patient was most likely billed 300-600 dollars

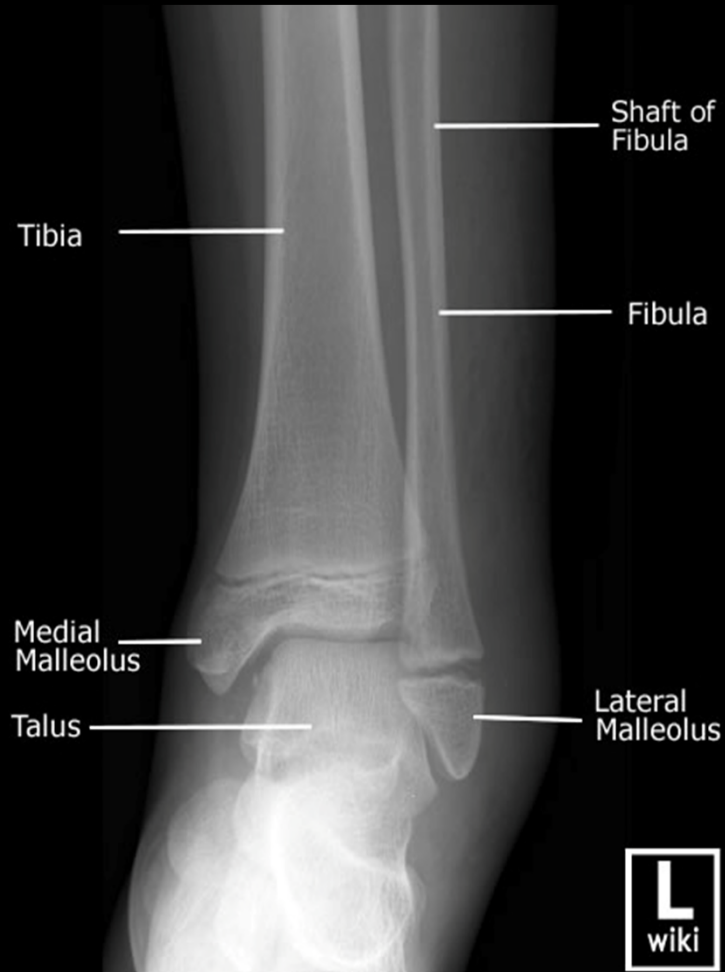

Patient: 10/ 24/2019: Plain Radiographic Film in AP and Lateral views showing a minimally displaced Salter Harris II Fracture of the distal tibia (of note – not original image due to formatting issues)

Plain Xray radiograph film in AP and Lateral view of an 11 year old boy

<https://www.newchoicehealth.com/places/texas/houston/x-ray>

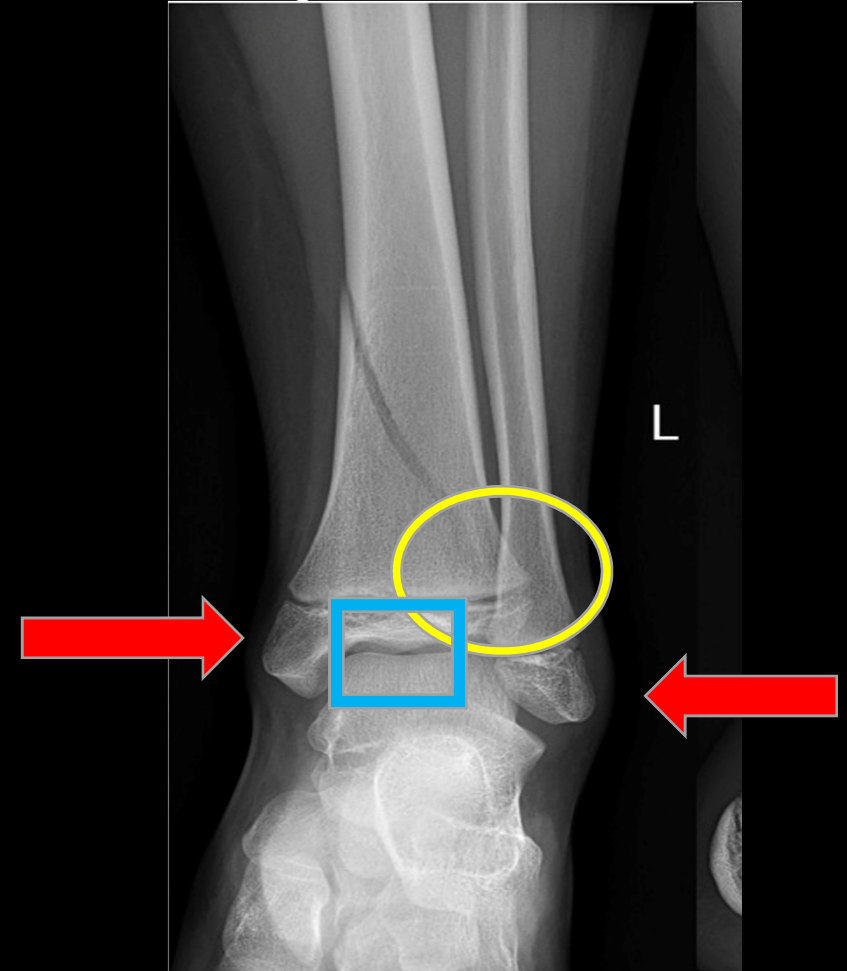
# Breaking it Down: Is this a sufficient study



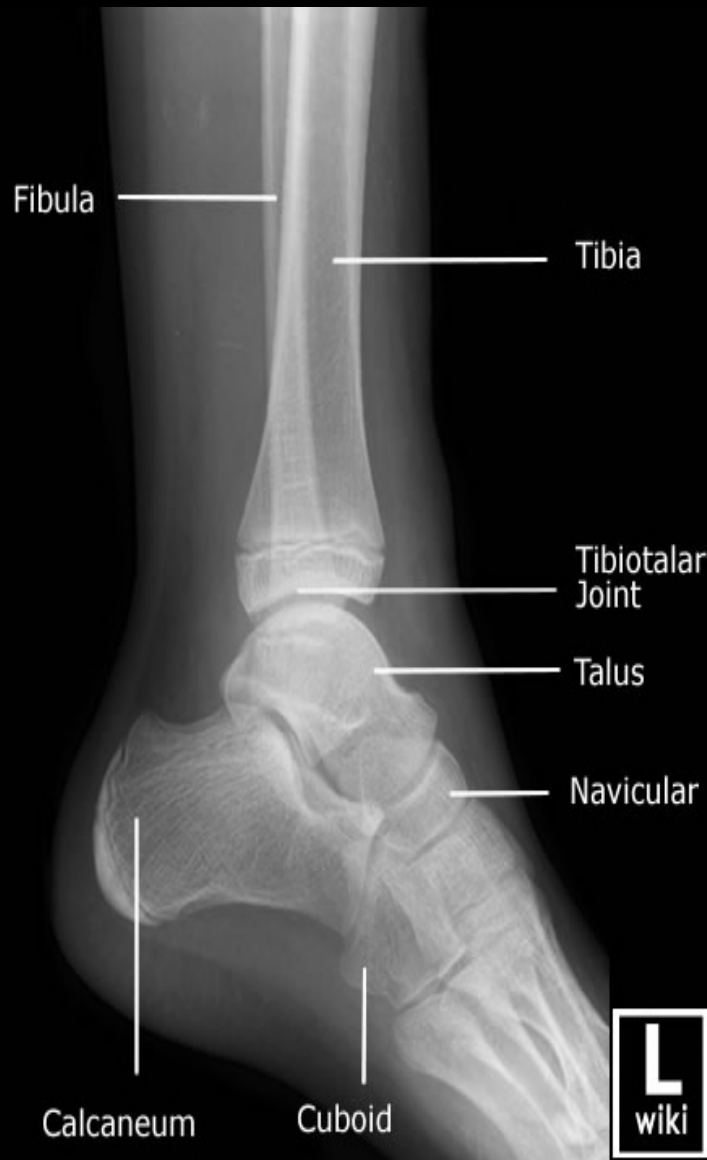Correct example of AP radiograph

The AP View should:

- Have the distal fibula slightly superimposed on the tibia
- The lateral and Medial Malleoli should be in profile
- Tibiotalar space should be open



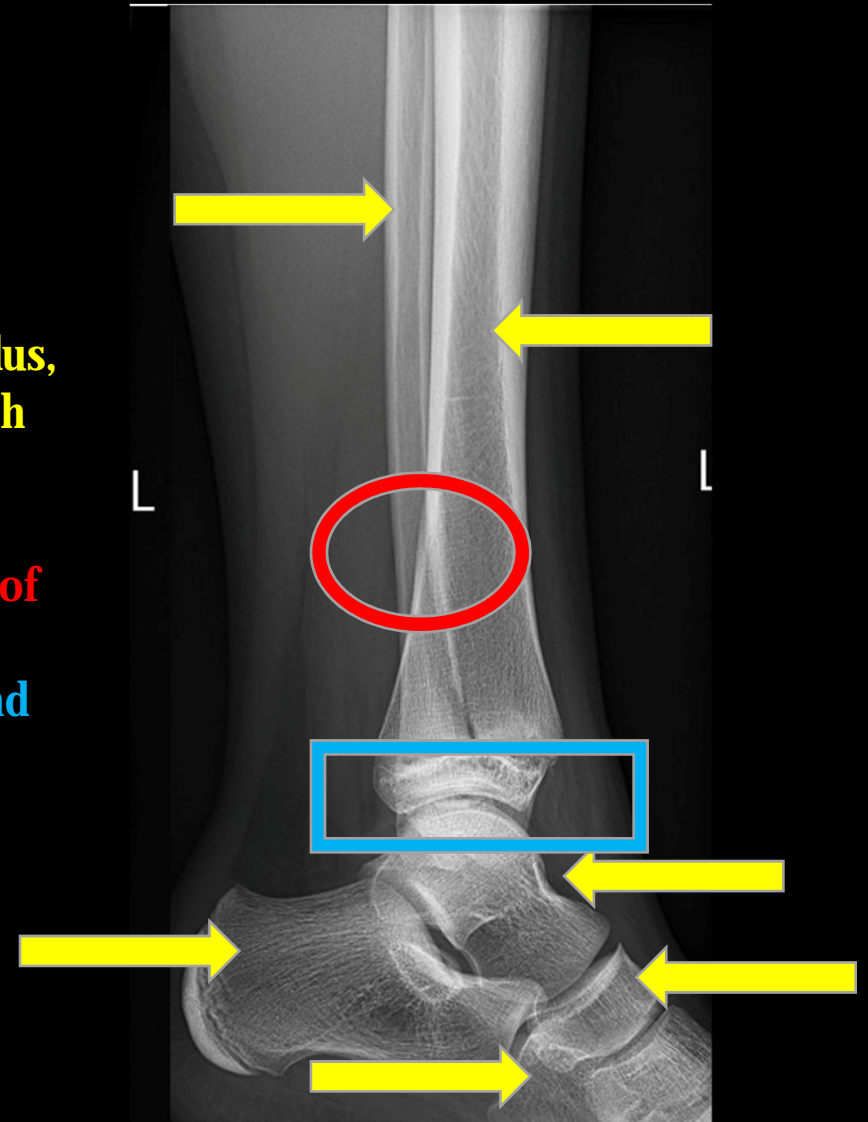
Did our study match up?



**Correct example of Lateral View**

The lateral view should:

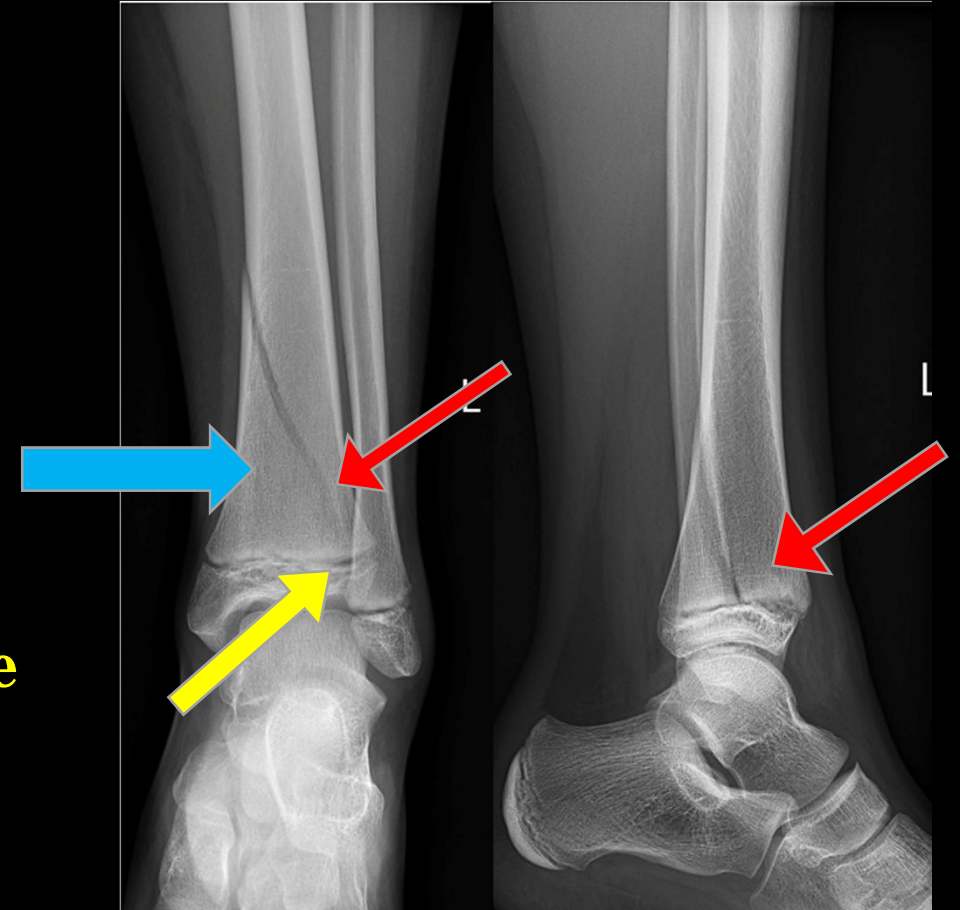
- **Be able to assess the tibia, fibula, talus, cuboid, navicular, calcaneus, and fifth metatarsal**
- **The distal fibula should be superimposed by the posterior part of the distal tibia**
- **The joint space between the tibia and talus should be uniform**



**In our model film we are missing some of the cuboid and we are not able to visualize the fifth metatarsal well**

# Key Imaging Findings

- Patient PMH: previously healthy
- Patient CC: Pain, swelling and inability to bear weight on left lower extremity.
- Image findings: **Salter Harris II ( Above)**
  - Distal tibia physeal fracture
  - Salter Harris II fracture of the distal left tibia with mild displacement
  - **Fracture of the epiphyseal plate and fracture of the metaphysis**
  - **The fracture line extends into the metaphysis**
  - **Small piece of metaphysis can be seen as wedge shaped or a "corner sign" at the edge of metaphysis**



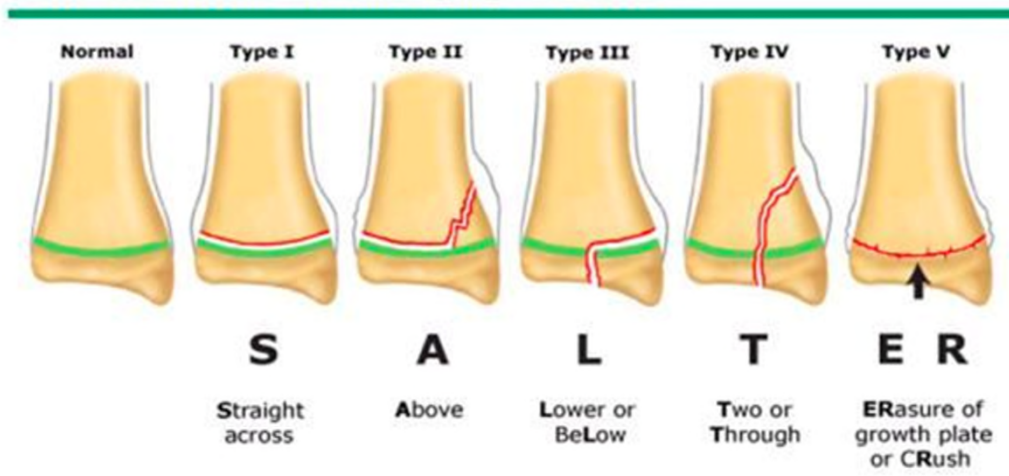
# Differential Diagnosis

1. Salter Harris Fracture Type II
2. Child abuse
3. Sprain (clinically)
4. Contusion (clinically)

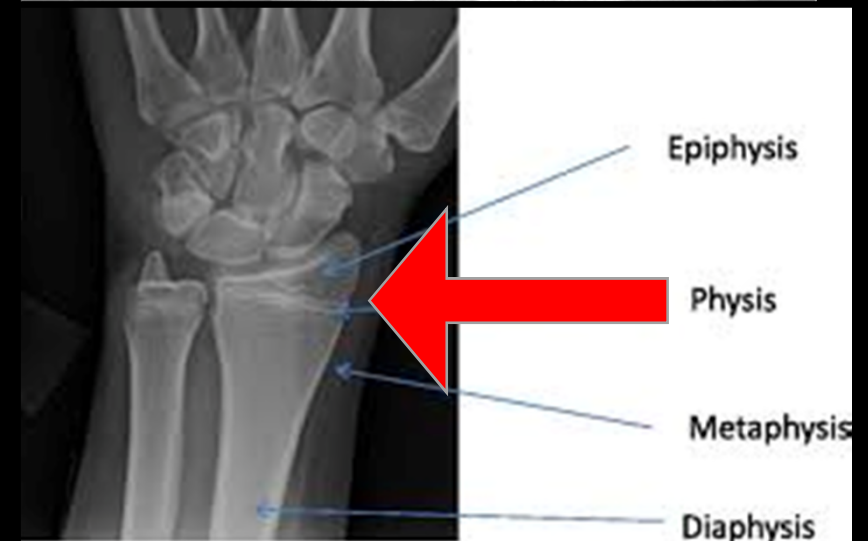
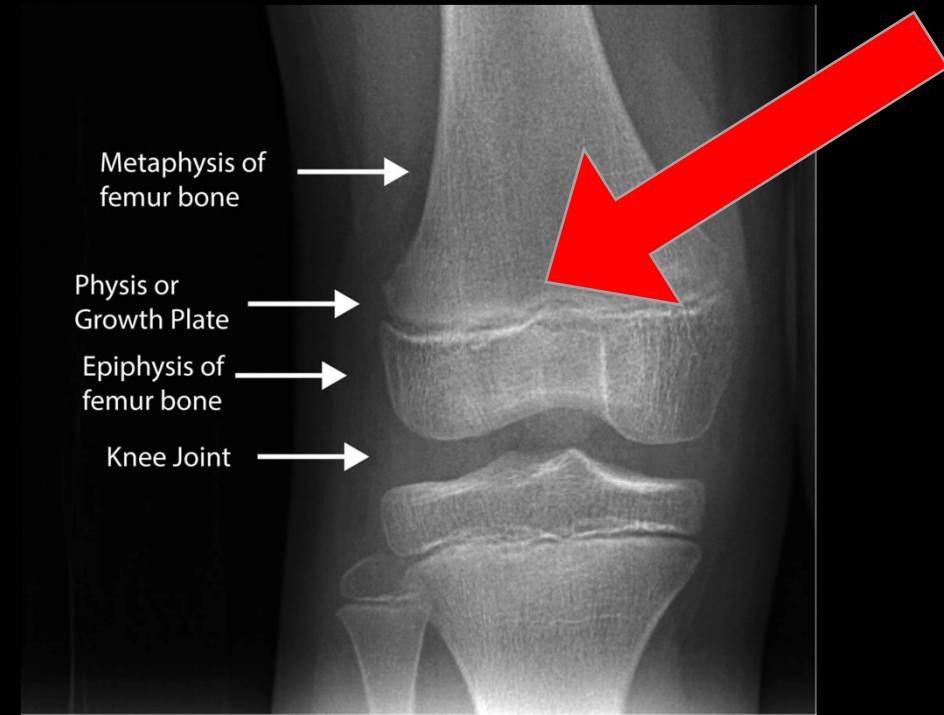


# Salter Harris Fractures: Classification

Salter-Harris classification of physeal fractures



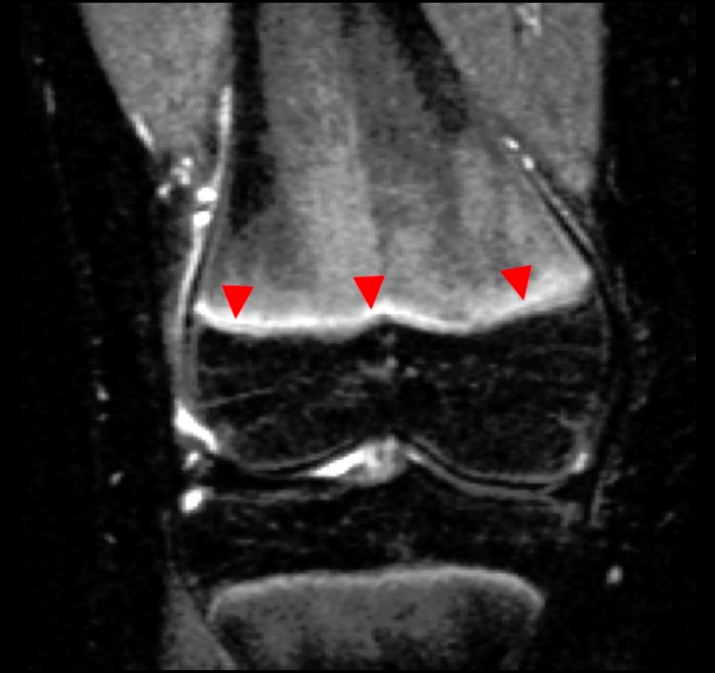- Injuries to the extremities of children are common, and often will involve the growth plate
- 15% of fractures of children involve the growth plate
- The Salter Harris system was first created in 1963 and based on radiographic appearance and the prognosis for growth disturbances.
- **SALTER** is also used as a mnemonic to characterize the fracture



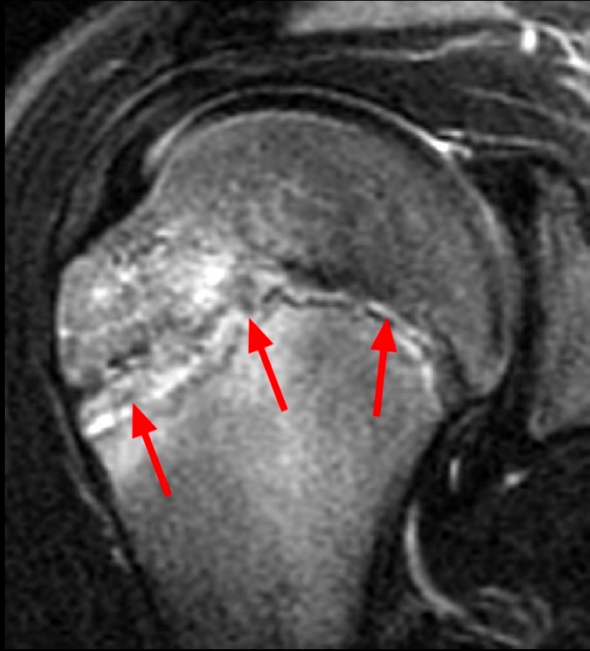


# SALTER HARRIS TYPE I:

- **About:**
  - Salter I (**S-lipped**): This fracture line extends through the physis or within the growth plate- this means that the fracture is usually only broken cartilage
  - Slipped capital femoral epiphysis is a manifestation of type (
- **Demographics:**
  - Usually younger children
- **Causes:**
  - It is usually due to a longitudinal force that is applied to the physis.
- **Diagnosis:**
  - Difficult to diagnose on X-ray and is usually made by a clinical diagnosis that includes swelling, tenderness, and decreased range of motion.
  - DO NOT exclude a salter Harris type 1 fracture due to a negative XRAY
- **Treatment:**
  - Usually treated with a cast or a CAM boot with weight bearing as tolerated.
- **Prognosis:**
  - Prognosis is good. Type 1 fracture heals without need for intervention and rarely results with complications.



**Figure 3:** A fat-suppressed T2-weighted coronal image of a SH 1 fracture through the distal femoral physis demonstrating increased signal intensity (arrowheads) in the growth plate relative to the tibial growth plate.



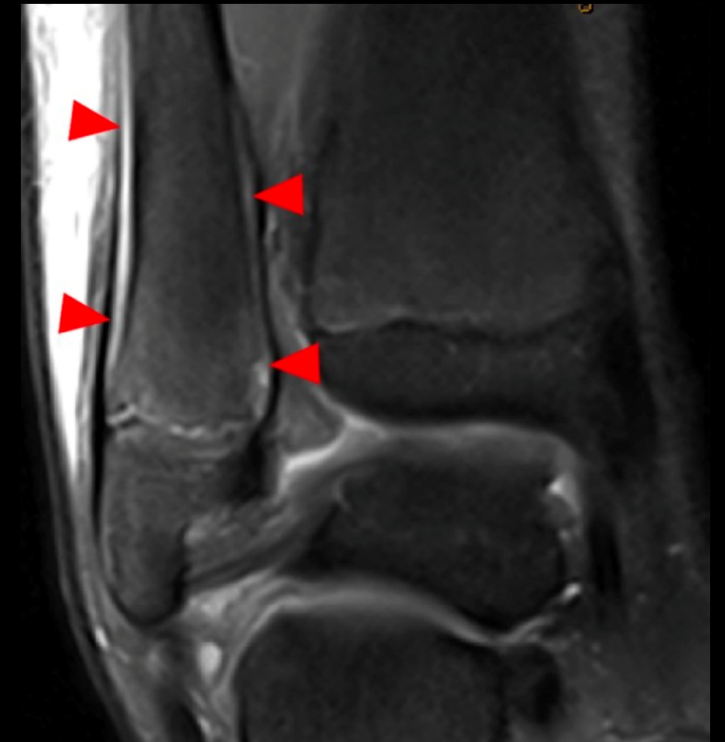Widening and abnormal signal intensity across the growth plate of the proximal humerus, indicating little league shoulder, a variation of a SH 1 fracture.

The distal fibula is a common site for a SH 1 fracture. Coronal proton density-weighted with fat-suppression

**MRI of the ankle and foot  
would cost anywhere between  
500-1500**

<https://www.newchoicehealth.com/places/texas/houston/mri>

## Type I: Physis Fracture



# SALTER HARRIS TYPE II

- **About:**

- Salter II ( **A-bove** ): This fracture extends through both the physis and the metaphysis, ABOVE the physis. It can be similar to type 1, but has more metaphyseal involvement

- **Demographics:**

- Most common Salter fracture- constitutes 85% of fractures.
- Most frequent in ages 3-7 , but is the most common type over the age of 10

- **Diagnosis:**

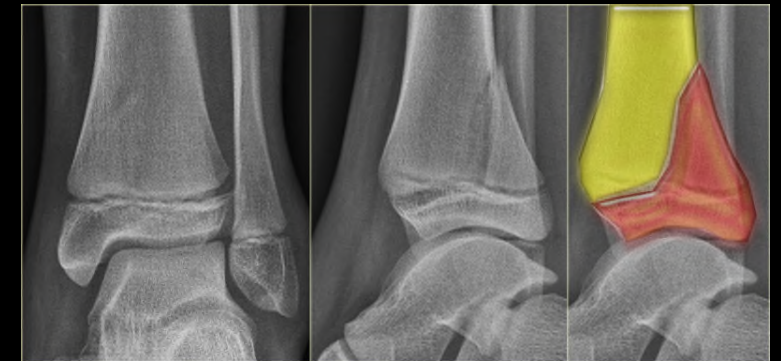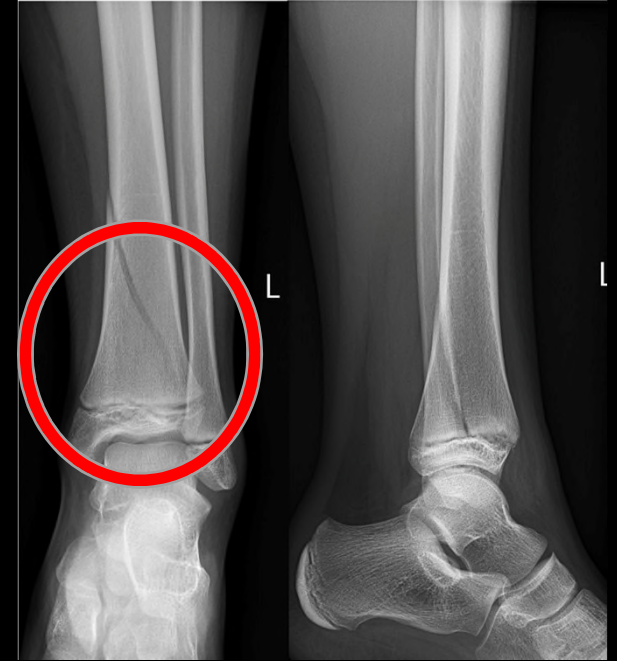- Made with XRAY and can sometimes be made with CT or MRI
- Many times a small part of the metaphysis is broken off partially and forms what is known as the “corner sign”

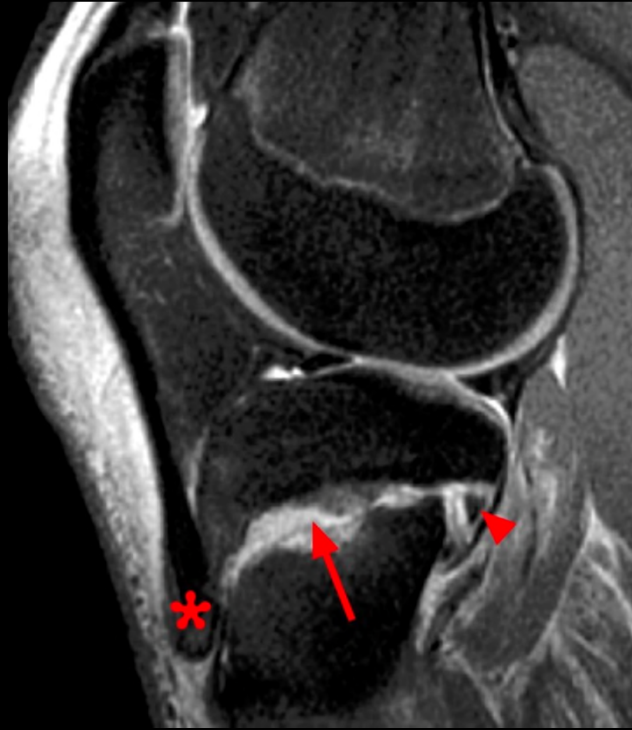- **Treatment:**

- Often repositioned with closed reduction under anesthesia and casted .

- **Prognosis:**

- Prognosis is good and complications are rare with the exception of fractures involving the distal part of the femoral bone which has a 43-73% rate of complications.

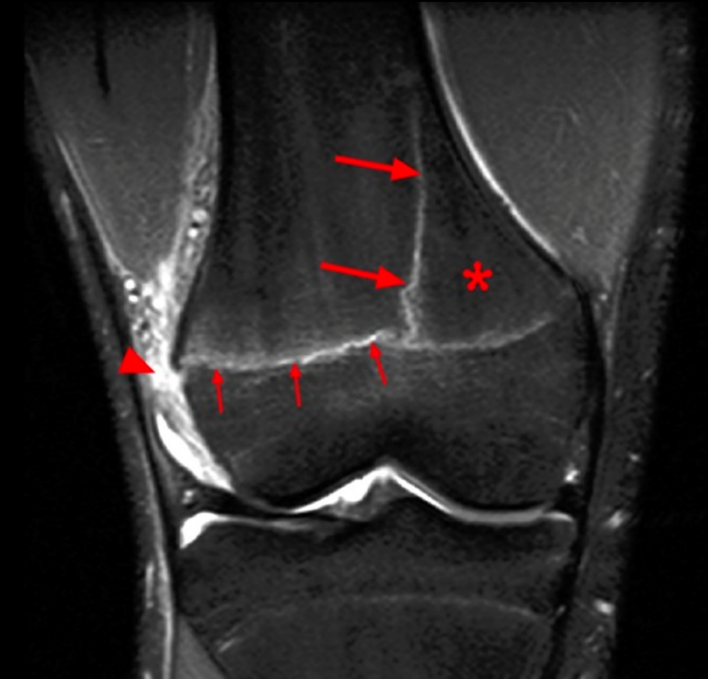



Sagittal MR image of the knee demonstrates a SH 2 fracture of the proximal tibia with displacement due to traction on the tibial tuberosity (asterisk). The physeal component (arrow) and the Thurston Holland fragment (arrowhead) are indicated.

## Type II: Metaphysis and Physis fracture

SH 2 of the distal femur with the Thurston Holland fragment (asterisk) created by a vertical metaphyseal fracture (large arrows) and a horizontal fracture through the physeal plate (small arrows). A tear of the periosteum (arrowhead) is present along the distraction side.





# SALTER HARRIS TYPE III

## About:

- Salter III ( **L- LOWER** ): This fracture extends from the physis into the epiphysis and separating part of it, together with the growth plate, from the metaphysis.
- The articular cartilage may also get partially fractured

## Demographics:

- Usually involves older children whose growth plate is partially closed.
- Common in the distal tibia – **Tillaux** fracture

## Diagnosis:

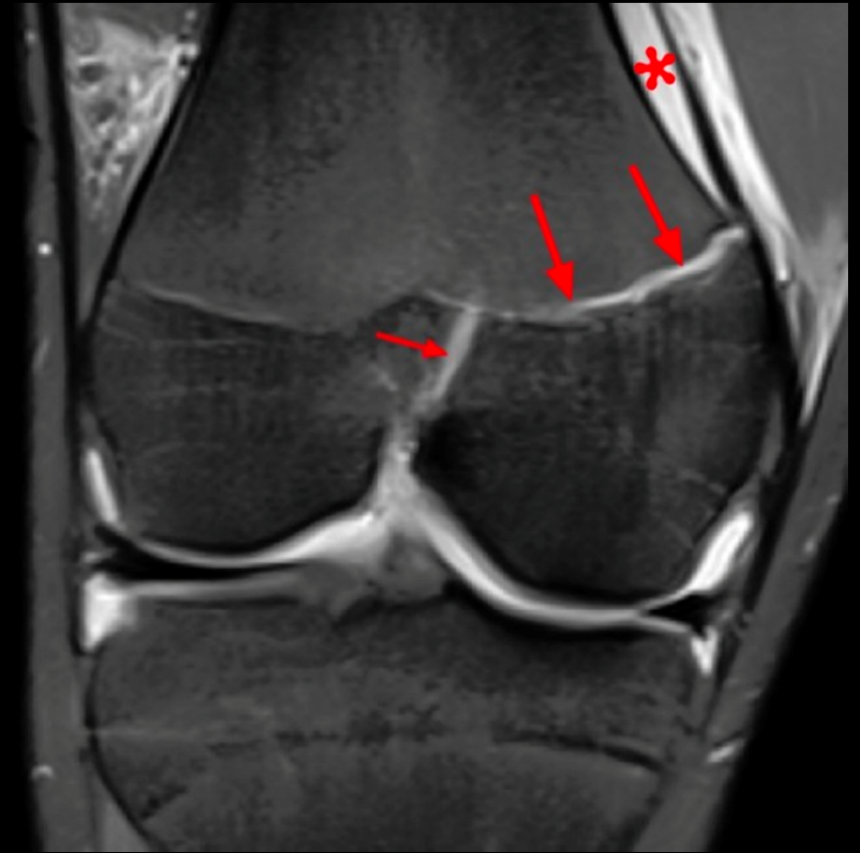- Diagnosed by XRAY, CT, MRI
- The fracture through the growth plate can only be seen on CT
- Can be thought of as a type 1 fracture with an additional epiphysis fracture

## Treatment:

- Usually requires surgery
- Early anatomical reduction and fixation with screws give best outcomes

## Prognosis:

- Concerning for complications as the joint cartilage is disrupted by the fracture.
- Long term risk: crooked ankle due to improperly healed joint
- Prognosis is good if blood supply of the split epiphyseal fragment is remained, and if there is no dislocation.



Coronal fluid-sensitive MR image of the knee shows a SH 3 fracture with a sagittal fracture of the epiphysis (small arrow) and axial fracture of the growth plate (larger arrows). Mild angulation results in incongruity of the articular surface. The periosteum is elevated by hematoma (red asterisk).

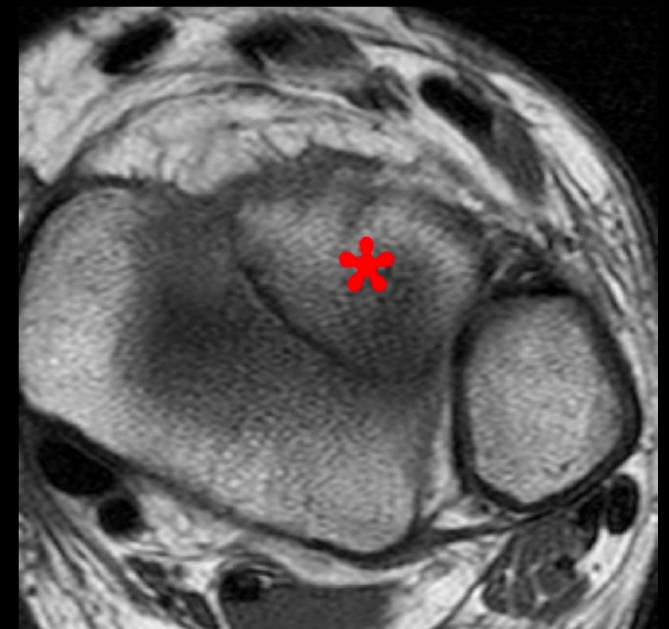
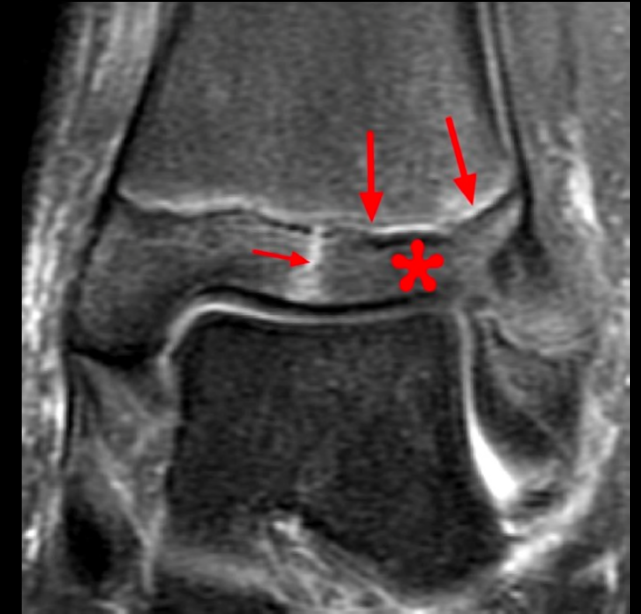
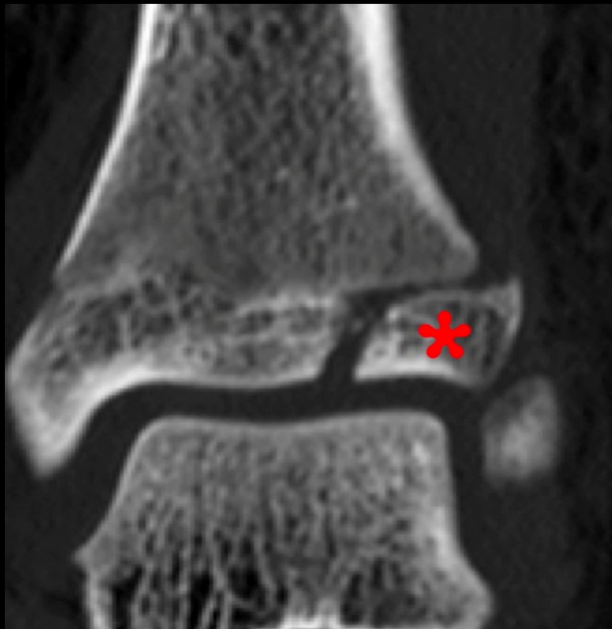
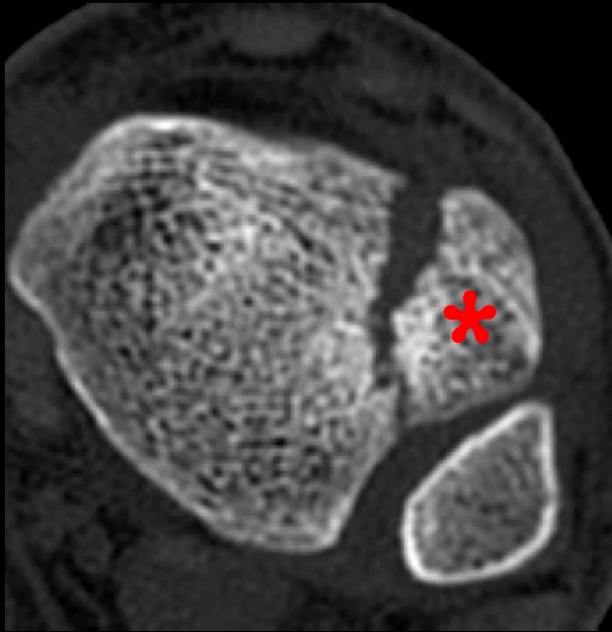
# Type III Salter Harris

Coronal and axial CT and MR images of the ankle (different patients) demonstrate a Tillaux fracture with a sagittal oriented fracture through the epiphysis of the distal tibia (small arrow) and the axial fracture through the growth plate (large arrows). The displaced epiphyseal component (asterisk) is readily apparent. The coronal CT image demonstrates the fusing growth plate which is typical for this fracture.

Tillaux fracture: fracture of anterolateral tibial epiphysis

"CT of the ankle and foot would cost up to \$11,000"

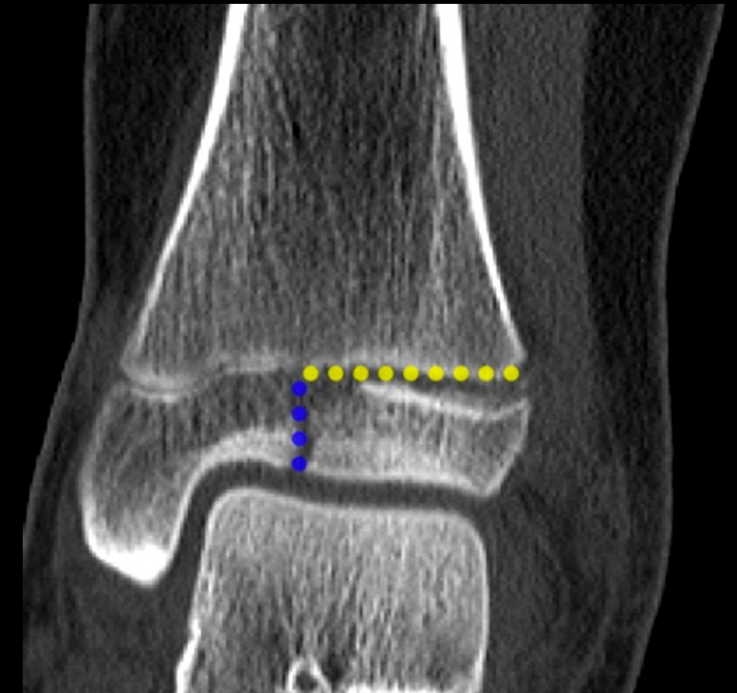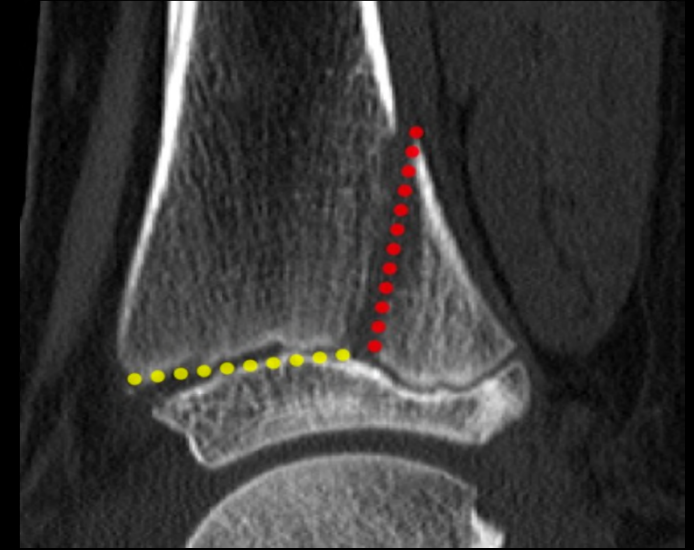
<https://www.newchoicehealth.com/ct-scan/cost>





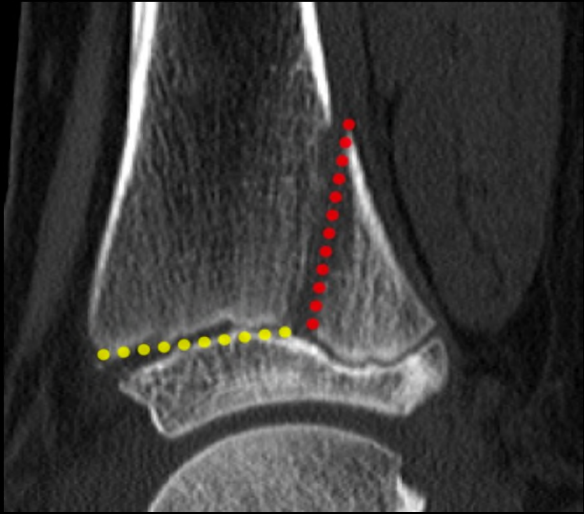
# SALTER HARRIS TYPE IV

- **About:**
  - Salter IV( **T- THROUGH/TWO** ): Is also a intra- articular fracture; however, this fracture passes through the epiphysis, physis and metaphysis.
- **Demographics:**
  - Common type: Triplane Fracture
  - It is commonly seen in the medial and lateral condyles and epicondyles of the distal humerus and in the medial malleolus.
- **Diagnosis:**
  - Diagnosed by XRAY, CT, MRI
  - Triplane fracture:
    - Vertical component through epiphysis
    - Horizontal component through the growth plate
    - Oblique component through the metaphysis
- **Treatment:**
  - Surgical treatment: proper reduction of the articular surfaces and precise alignment of the growth plate is needed
  - If any displacement: open reduction usually needed, but some may be able to do closed reduction and percutaneous fixation
- **Prognosis:**
  - Poor prognosis with risk for growth retardation, althered joint mechanics and functional impairment.
  - Growth arrest is common

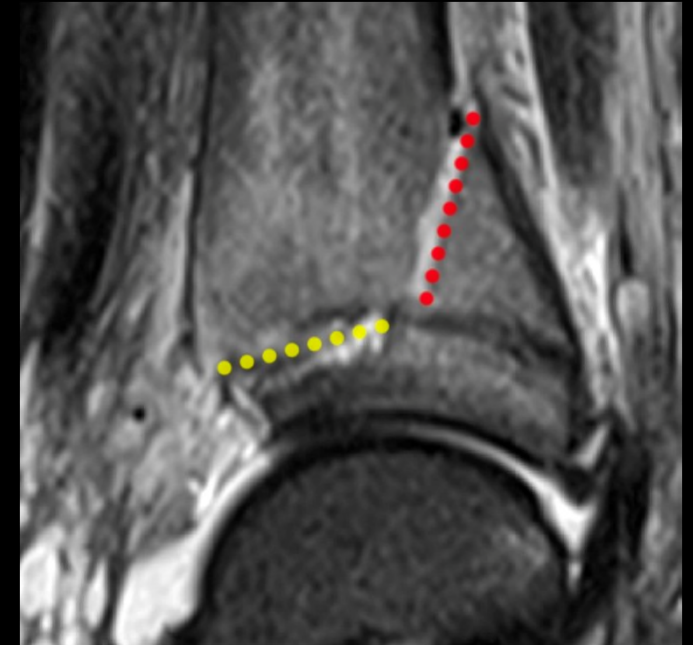


# Salter Harris IV

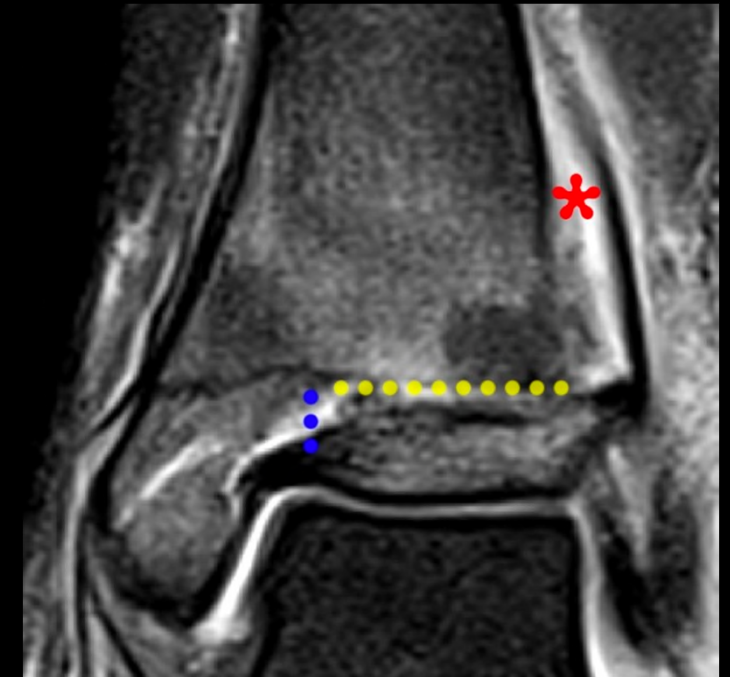
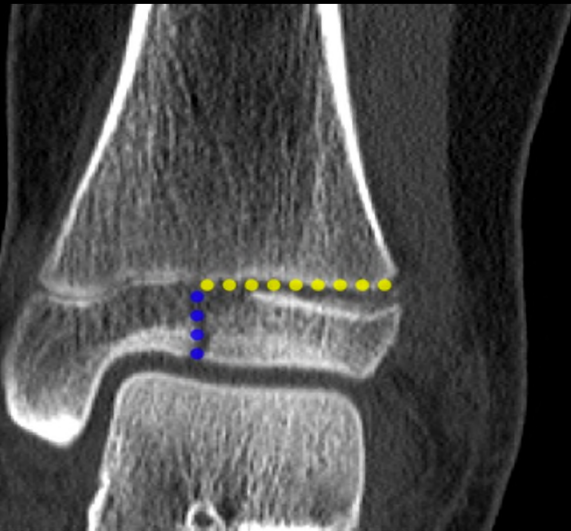Sagittal, Coronal, Axial CT images of the ankle with a SH 4 triplane fracture.



Coronal and sagittal MRI

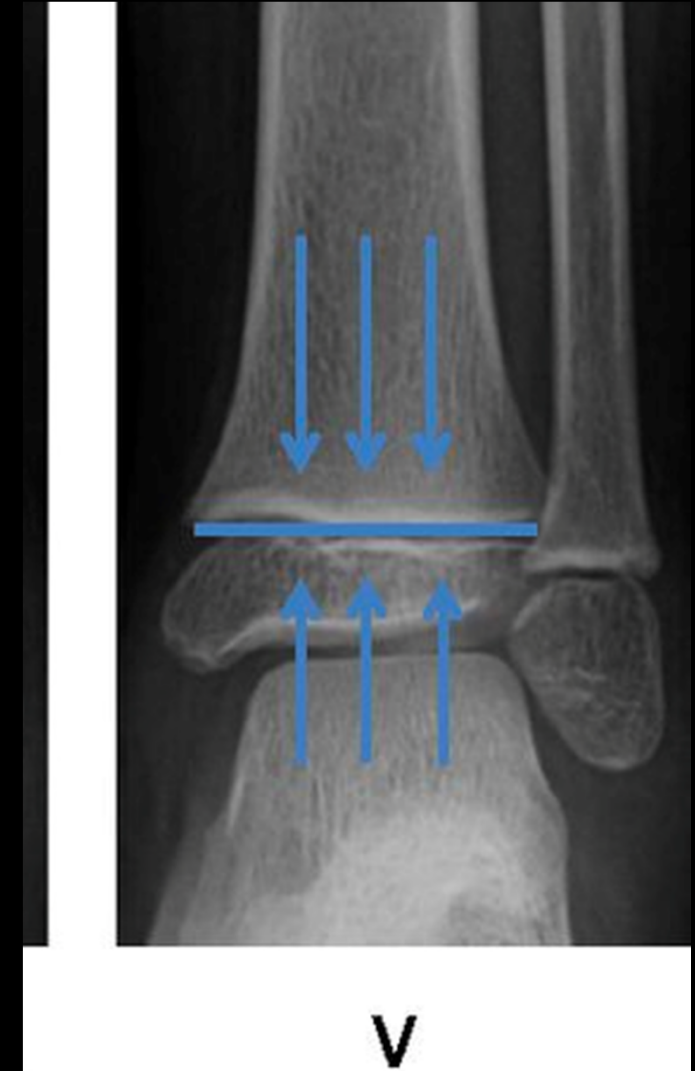


1. A coronal fracture extends through the posterior metaphysis of the distal femur (red line)
2. Horizontal fracture through the lateral growth plate (yellow)
3. Sagittal fracture through the epiphysis (blue line)

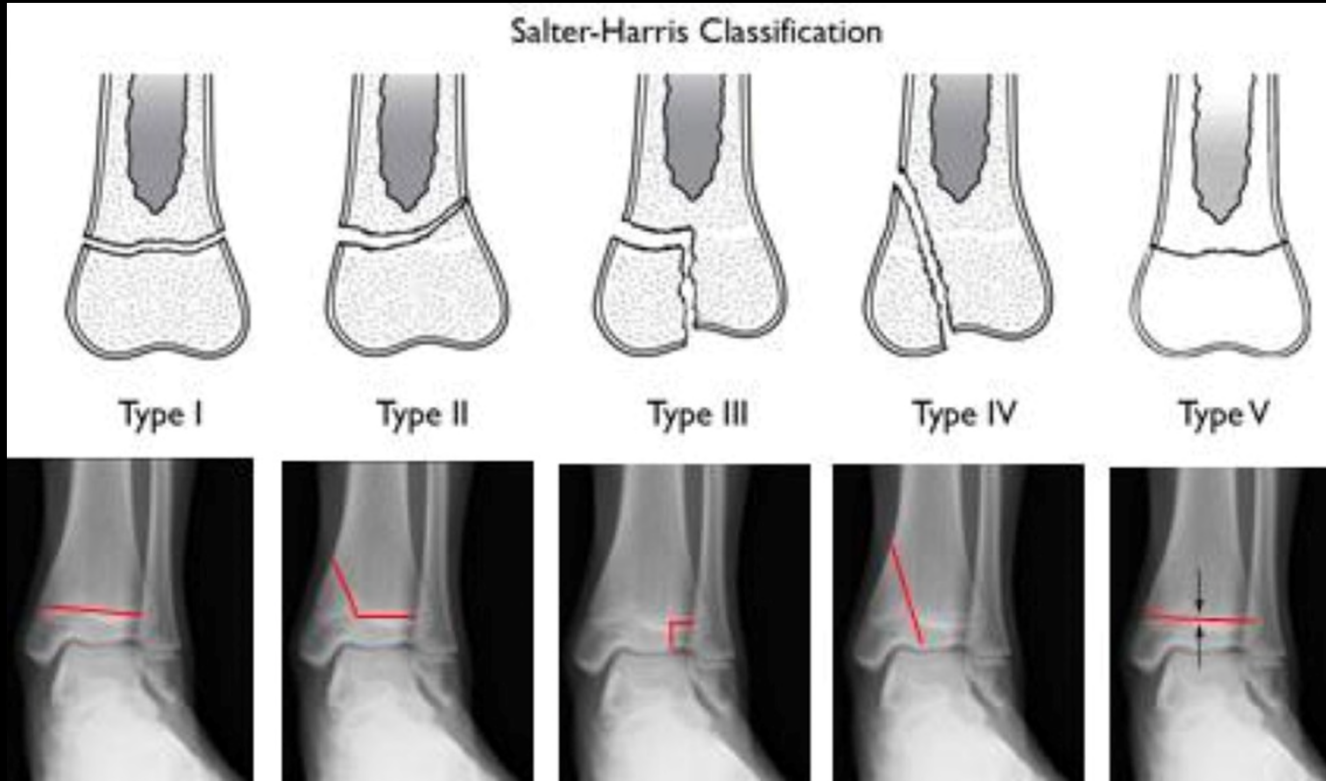

# SALTER HARRIS V

- **About:**
  - Salter V ( **ER-ASURE/CRUSH** ): This fracture is due to compression of the growth plate and can disrupt the germinal matrix and vascular supply.
- **Demographics:**
  - Very rare- seen with electric shock, frostbite, and irradiation.
  - Usually due to severe injury
- **Diagnosis:**
  - Can be radiographically occult and radiograph may appear normal!
  - Should consider a type V with a symptomatic child + normal radiograph in the correct setting.
  - Can have evidence of physeal widening
  - May need AP and Latera views to delineate the fracture type properly + a comparison image with the other extremity
  - DIAGNOSIS IS OFTEN DELAYED
- **Treatment:**
  - If growth arrest occurs- may need to have surgical resection of the bone bridges to allow optimization of surgical treatment
  - May need later treatment to restore alignment
- **Prognosis:**
  - The worst prognosis, but less frequent.
  - Premature growth arrest is nearly inevitable complications.



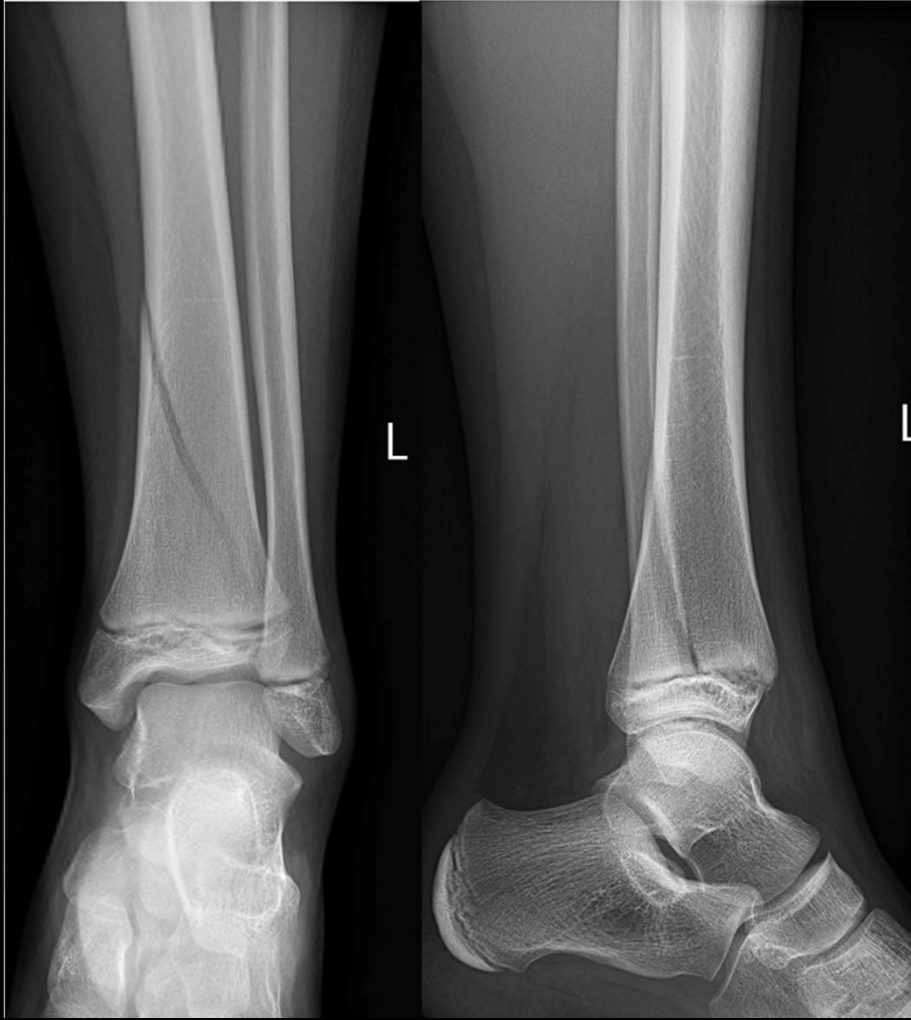# TREATMENT SUMMARY



- **SALTER HARRIS I:**
  - Cast or boot
- **SALTER HARRIS II:**
  - Cast or boot + closed reduction if misalignment
- **SALTER HARRIS III:**
  - usually open reduction internal fixation
- **SALTER IV:**
  - open reduction internal fixation
- **SALTER V:**
  - often delayed diagnosis, must realign in most cases.



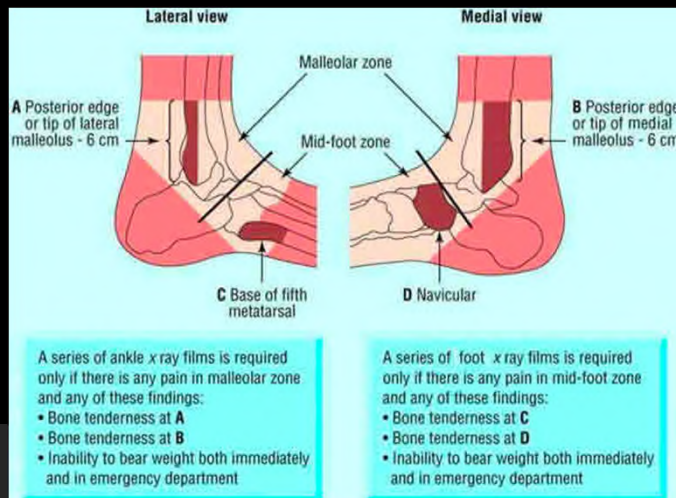
# OUR PATIENT



- Our patient was diagnosed with a Salter Harris Type II fracture
- He had + clinical symptoms that correlated with the Xray imaging (particularly + corner sign)
- The radiologist read it as mildly displaced and therefore there was discussion of closed reduction
- Pt would definitely need casting+ follow up 7-10 days later
- He had a good prognosis with small % chance of complications.

# ACR appropriateness Criteria

- This case was in accordance with the ACR appropriateness criteria as the patient was:
  - >5 years old
  - Met Ottawa ankle rule
  - Was unable to bear weight after injury
  - Had point tenderness over medial malleolus, posterior edge of the lateral malleolus, and talus
  - Could not ambulate
- We obtained an XRAY of the ankle and foot bilaterally



Date of origin: 1995  
Last review date: 2014

**American College of Radiology  
ACR Appropriateness Criteria®**

**Clinical Condition:** Acute Trauma to the Ankle

**Variant 1:** Adult or child >5 years old. Patient meets Ottawa Ankle Rules:

1. Inability to bear weight immediately after the injury, OR
2. Point tenderness over the medial malleolus, the posterior edge or inferior tip of the lateral malleolus, talus, or calcaneus, OR
3. Inability to ambulate for 4 steps in the emergency department.

Radiologic Procedure	Rating	Comments	RRL*
X-ray ankle	9	Obtain AP, lateral, and mortise views.	⊕

**Rating Scale:** 1,2,3 Usually not appropriate; 4,5,6 May be appropriate; 7,8,9 Usually appropriate

**\*Relative Radiation Level**

**ACR**  
AMERICAN COLLEGE OF  
RADIOLOGY

**Appropriateness Criteria**

**Acute Trauma to the Ankle**

Variant 1: Adult or child >5 years old. Patient meets Ottawa Ankle Rules: 1. Inability to bear weight immediately after the injury, OR 2. Point tenderness over the medial malleolus, the posterior edge or inferior tip of the lateral malleolus, talus, or calcaneus, OR 3. Inability to ambulate for 4 steps in the emergency department.

Procedure	Appropriateness Category	SOE	Adult RRL	Peds RRL	Rating	Median	Final Tabulations								
							1	2	3	4	5	6	7	8	9
X-ray ankle	Usually appropriate		⊕ <0.1 mSv		9	n/a	0	0	0	0	0	0	0	0	0



# References

- Levine RH, Foris LA, Nezwik TA, et al. Salter Harris Fractures. [Updated 2019 Aug 13]. In: StatPearls [Internet]. Treasure Island (FL): StatPearls Publishing; 2019 Jan-. Available from: <https://www.ncbi.nlm.nih.gov/books/NBK430688>
- Kuleta-Bosak E, Bożek P, Kluczevska E, Tomaszewski R, Machnik-Broncel J. Salter-Harris type II fracture of the femoral bone in a 14-year-old boy - case report. *Pol J Radiol*. 2010;75(1):92–97.
- Su AW, Larson AN. Pediatric Ankle Fractures: Concepts and Treatment Principles. *Foot Ankle Clin*. 2015;20(4):705–719. doi:10.1016/j.fcl.2015.07.004
- <http://radsourc.us/salter-harris-fractures/>
- <https://radiologyassistant.nl/musculoskeletal/ankle-special-fracture-cases>
- <https://radiopaedia.org/articles/salter-harris-classification?lang=us>
- [https://acsearch.acr.org/list?\\_ga=2.195459624.561464197.1573585329-601385636.1572890889](https://acsearch.acr.org/list?_ga=2.195459624.561464197.1573585329-601385636.1572890889)



Questions?